

Isolated nuclear oculomotor nerve syndrome due to mesencephalic hematoma

C. T. IŞIKAY, C. YÜCESAN, N. YÜCEMEN, A. ÇULCUOĞLU, N. MUTLUER
Ankara University Faculty of Medicine, Department of Neurology, Ankara, Turkey

Abstract

Unilateral third nerve palsy with bilateral superior rectus paresis and bilateral ptosis is a typical condition for nuclear oculomotor nerve syndrome. We report a case of nuclear oculomotor nerve syndrome due to mid-brain hemorrhage, as a rare cause.

A 73-year-old man presented with an abrupt onset of double vision and difficulty opening his eyes. He had uncontrolled hypertension in his history. Neurological examination revealed right oculomotor palsy with impairment of bilateral upward gaze and bilateral ptosis. MRI showed a mesencephalic area of increased T1 signal and decreased T2 signal consistent with a sub-acute hematoma.

It is emphasized that isolated mesencephalic hemorrhage may be the cause of the nuclear oculomotor nerve syndrome without associated neurological signs.

Key words : Mesencephalic hematoma ; nuclear oculomotor nerve syndrome.

Introduction

Hemorrhagic lesions are rarely limited to the midbrain and midbrain vascular lesions are usually associated with other neurological signs, such as pyramidal tract dysfunction, abnormalities of coordination, and impaired consciousness (Weisberg, 1986). Disorders of the oculomotor nerve at its nuclear source are also rarely encountered (Brazis, 1991). Because of the complex anatomic configuration, unilateral damage of the third nerve nucleus results in bilateral ocular motor abnormalities. Diagnostic signs of nuclear oculomotor lesions are ipsilateral complete oculomotor palsy, bilateral ptosis, and bilateral superior rectus paresis (Brazis, 1991). There are previous case reports of mesencephalic hematomas presenting with a nuclear oculomotor nerve syndrome associated with other neurological signs (Gaymard *et al.*, 1990 ; Nighoghossian *et al.*, 1991 ; Getenet *et al.*, 1994). Here, we report a case of midbrain hematoma presenting with a nuclear oculomotor nerve syndrome but no other neurological signs, as an exceedingly rare condition.

Case Report

A 73-year-old man presented with the abrupt onset of bilateral ptosis and horizontal diplopia which had started a week before his admission. He had a history of chronic hypertension and chronic obstructive lung disease and had been using tobacco for many years. His blood pressure was 180/100 mmHg. He was alert and well oriented. He did not complain of vertigo, headache, nausea or vomiting.

Neurological examination revealed near complete right and incomplete left ptosis (Fig. A1). He could open his eyes only by lifting his lids manually. His right pupil was mydriatic and unreactive to light and accommodation while his left pupil was 3 mm in diameter and reactive to light (Fig. A2). His visual field assessed by confrontation and his visual acuity were normal. In primary position, the right eye was deviated outward and downward, and the left eye was deviated downward slightly (Fig. A2). The adduction, upward and downward gaze of the right eye were absent (Fig. A4-6). The abduction of the right eye was normal (Fig. A3). All movements of the left eye were normal, except for the limitation of upgaze, especially on abduction which was indicating superior rectus muscle palsy (Fig. A7-8). Doll's head eye phenomenon toward the upward direction and Bell's phenomenon had disappeared bilaterally. The other neurological findings were normal.

Results of blood tests revealed polycythemia, other parameters did not show any abnormality. MRI performed in the second week demonstrated high signal intensity on T1 weighted images (Fig. B1) and low signal intensity on T2 weighted images (Fig. B2) in the dorsal paramedian portion of the mesencephalon consistent with the early hemoglobin stage of a subacute hematoma. The lesion was located primarily in an area compatible with the oculomotor nuclear complex. Cerebral angiography of the carotid and basilar arterial systems was normal.

During the following weeks, a gradual improvement of oculomotor function was observed. On neurological examination a year after onset of the

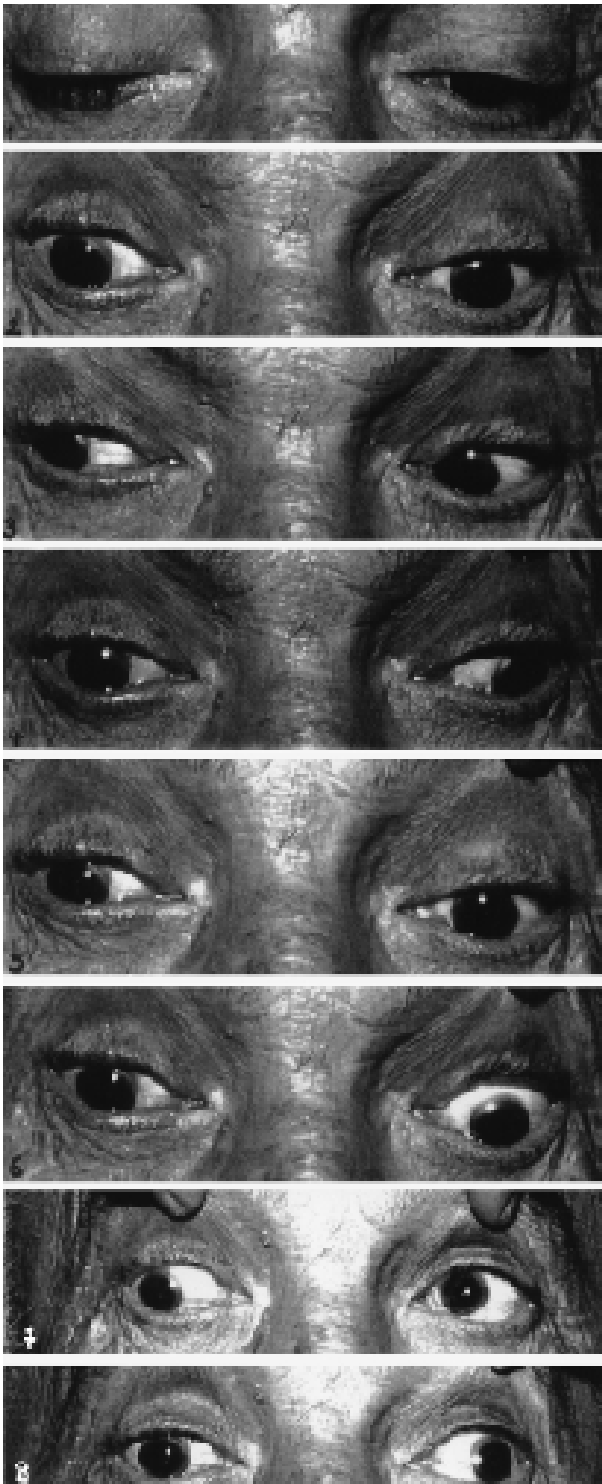

FIG. A. — Eye movements a week after stroke
 1-Primary position, 2-Primary position ; his lids were lifted manually, 3-Right gaze,
 4-Left gaze, 5-Upward gaze, 6-Downward gaze, 7-Right upward gaze, 8-Left upward gaze.

disease, the patient had no ptosis (Fig. C1). The right pupil was moderately dilated and unreactive to light and accommodation (Fig. C1). He was still complaining of horizontal diplopia. There was ongoing limitation of the elevation bilaterally which had partially improved in the left eye, and the limitation of the adduction in the right eye

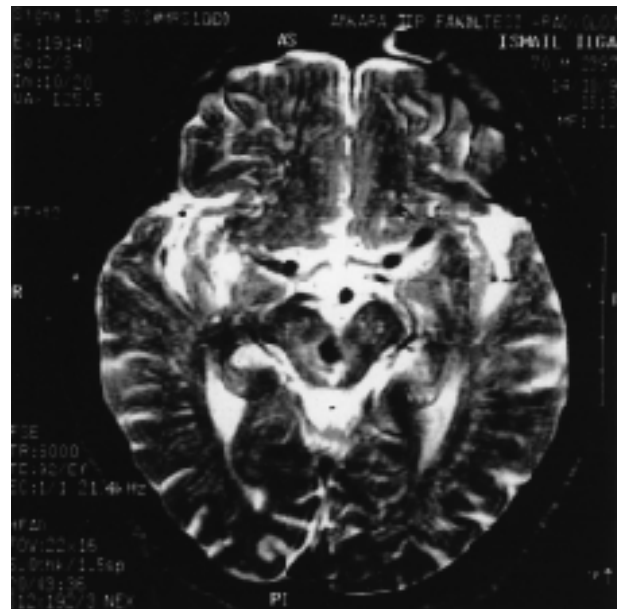
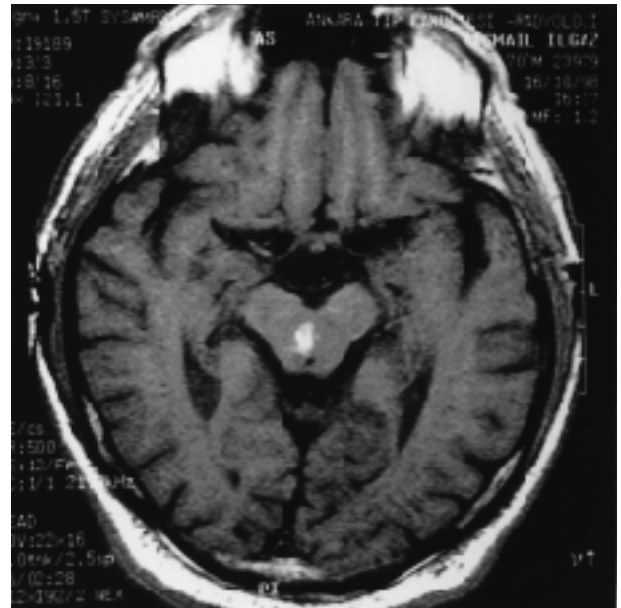


FIG. B. — MRI performed a week after stroke
 1-MRI, axial T1 weighted image, 2- MRI, axial T2 weighted image.

had almost completely disappeared. (Fig. C3-4). Convergence of the right eye was restricted to the midline (Fig. C6). The remaining ocular movements were found to be normal (Fig. C2,5) MRI performed at this time revealed a linear hypointense lesion remaining on both T1 and T2 weighted images, consistent with the hemosiderin stage of a chronic hematoma (Fig. D1-2).

Discussion

Patients with mesencephalic hematoma usually present with impaired vertical eye movements, impaired consciousness, pyramidal tract dysfunction and abnormalities of coordination (Weisberg, 1986). Small lesions of the proximal oculomotor

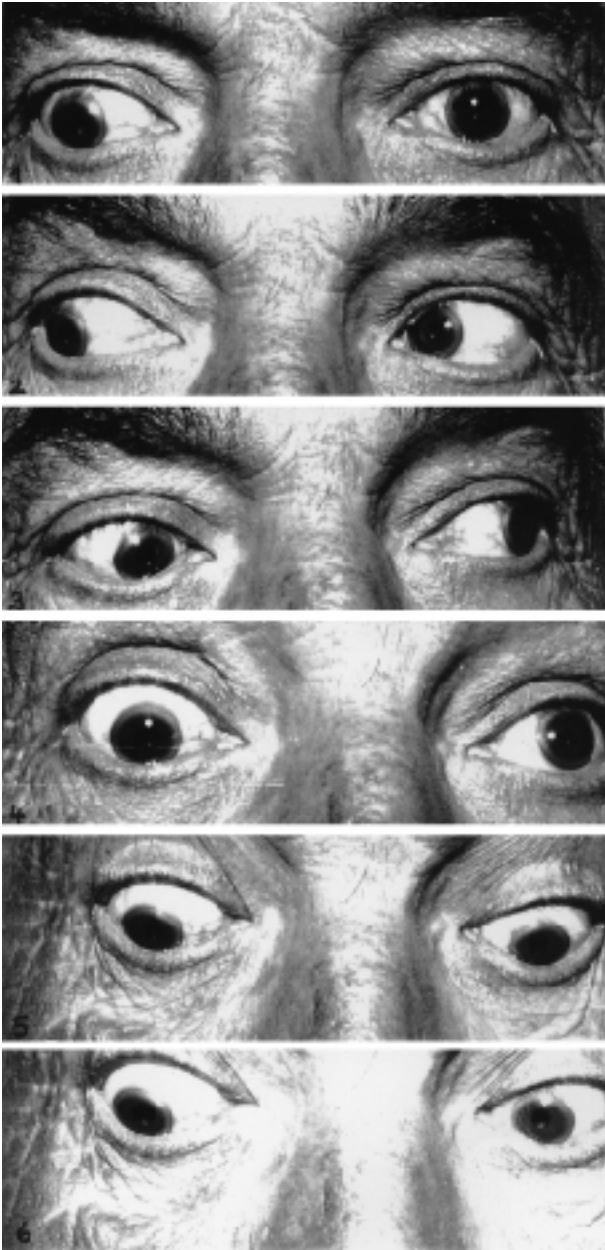

FIG. C. — Eye movements a year after stroke
1-Primary position, 2-Right gaze, 3-Left gaze, 4-Upward gaze, 5-Downward gaze, 6-Convergence.

fascicles or nuclear complex are seen very rarely. A few patients have been described in whom mid-brain hemorrhage exhibited nuclear oculomotor palsy as a predominant neurological manifestation (Stern and Bernick, 1986 ; Gaymard *et al.*, 1990 ; Getenet *et al.*, 1994).

Stern and Bernick (1986) reported a case of dorsal mesencephalic hemorrhage presented with bilateral partial ptosis and unilateral inferior rectus paralysis suggesting incomplete nuclear oculomotor palsy. Gaymard *et al.* (1990) reported a case of Weber syndrome presenting with a reversible nuclear oculomotor nerve syndrome caused by primary mesencephalic hemorrhage. The brain computed tomography of this patient demonstrated a mesencephalic hematoma in the ventral tegmen-

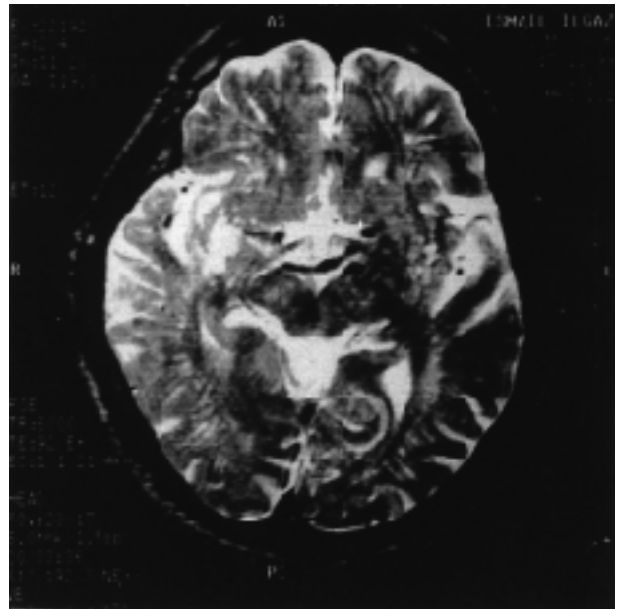
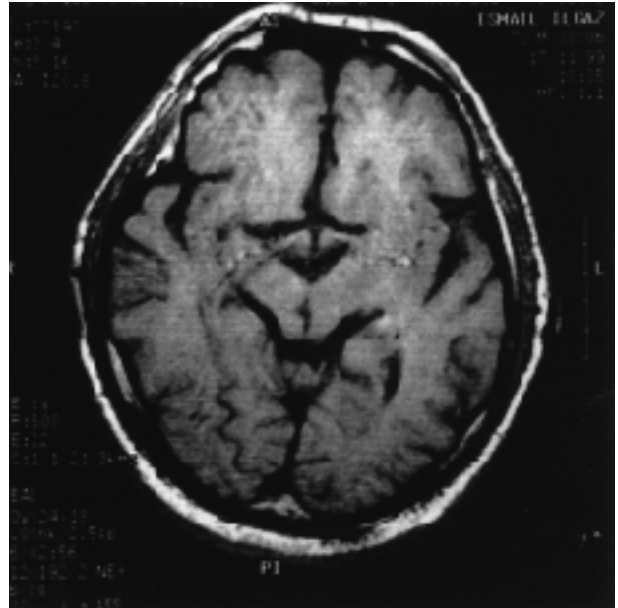


FIG. D. — MRI performed a year after stroke
1-MRI, axial T1 weighted image, 2- MRI, axial T2 weighted image.

tum. The improvement of the nuclear oculomotor syndrome in a week was explained as a result of the mass effect and the compression of the nuclear complex (Gaymard *et al.*, 1990). Getenet *et al.* (1994) described a boy with bilateral third nerve palsy arising from a nontraumatic mesencephalic hematoma caused by a cavernous angioma. However, this case also had vertical gaze palsy indicating the involvement of the rostral interstitial nucleus of the medial longitudinal fasciculus (ri-MLF) or the projections of the ri-MLF to the oculomotor complex (Getenet *et al.*, 1994). A 83-year-old man reported by Saeki *et al.* (2000) exhibited disorientation, right hemiparesis and bilateral oculomotor palsy due to hematoma in the dorsal midbrain tegmentum. Five days after his admission, he had

bilateral oculomotor palsy with unilateral pupillary dysfunction remaining

According to Warwick's scheme for the configuration of the oculomotor subnuclei, the central caudal nucleus supplies both levator palpebrae muscles and each superior rectus muscle is innervated by the contralateral subnucleus (Warwick, 1953). The fascicles of each superior rectus subnucleus cross the midline and pass through the contralateral subnucleus before reaching the opposite third nerve. Unilateral lesions of the oculomotor complex should therefore cause bilateral ptosis and binocular limitation of elevation due to a fascicular lesion of the ipsilateral superior rectus and nuclear lesion of the contralateral superior rectus (Dehaene *et al.*, 1987 ; Gaymard *et al.*, 1990 ; Brazis, 1991).

The Edinger-Westphal nucleus is a midline structure of the nuclear complex as well as the central caudal nucleus. The nuclear lesion in our patient was believed to spare the Edinger-Westphal nucleus, since the pupillary response was normal on one side as in the case of Saeki *et al.* (2000). The sparing of the Edinger-Westphal nucleus may be explained on the basis of topographic arrangement of the oculomotor subnuclei in the midbrain. It has been known that the Edinger-Westphal nucleus and its fascicles are located at the top of the nuclear complex (Brazis, 1991 ; Saeki *et al.*, 2000). Bilateral pupillary involvement with nuclear oculomotor palsy, therefore, is only expected in lesions with extension to the rostral midbrain. Unilateral pupillary unresponsiveness in our patient may be due to destruction of the pupillomotor fibers which are situated most medially among the oculomotor fascicles.

In our patient, the left eye was slightly deviated downward in primary position, and the upgaze was limited especially on abduction, and did not show any improvement with oculocephalic maneuvers. We did not observe dissociated nystagmus in the left eye on left gaze. All these clinical observations supported that the medial longitudinal fasciculus (MLF) and ri-MLF, the structures in the vicinity of oculomotor complex, were not involved in our patient.

Our patient had bilateral and asymmetric ptosis, being worse ipsilateral to the lesion. A similar condition had been reported in two cases by Liu *et al.* (Liu *et al.*, 1991). It has been known that complete ptosis is not mandatory for a nuclear oculomotor nerve syndrome. Bilateral complete or incomplete ptosis is the hallmark of involvement of the central caudal subnucleus and localizes the lesions to the caudal oculomotor complex and its immediate vicinity (Glaser and Bachynski, 1990). In addition, this patient was admitted to our clinic a week after onset of his complaints. Therefore, the incomplete ptosis on the left side may also be due to partial recovery.

Isolated nontraumatic hemorrhagic lesions of the midbrain occur infrequently and primarily involve

the cerebral peduncle and tegmentum. Systemic hypertension and arteriovenous malformations represent the most common etiologies of primary hematomas of the mesencephalon (Sand *et al.*, 1986). We believe that our patient suffered a hypertensive midbrain hemorrhage, since he had untreated hypertension and cerebral angiography showed no vascular malformation.

This case indicates that the absence of associated neurological signs with oculomotor palsy especially favors nuclear localisation of the lesion, while fascicular lesions which are located more anteriorly are usually accompanied by other neurological signs such as hemiparesis, and cerebellar dysfunction.

REFERENCES

- BRAZIS P. W. Localization of lesions of the oculomotor nerve : Recent concepts. *Mayo. Clin. Proc.*, 1991, **66** : 1029-1035.
- GAYMARD B., LARMANDE P., TOFFOL B., AUTRET A. Reversible nuclear oculomotor nerve paralysis. Caused by a primary mesencephalic hemorrhage. *Eur. Neurol.*, 1990, **30** : 128-131.
- GETENET J. C., VIGHOTTO A., NIGHOGHOSSIAN N., TROUILLAS P. Isolated bilateral third nerve palsy caused by a mesencephalic hematoma. *Neurology*, 1994, **44** : 981-982.
- GLASER J. S., BACHYNSKI B. Infranuclear disorders of eye movement. In : *Neuro-Ophthalmology*. Second edition. J. B. Lippincott Company, 1990, 372-373.
- LIU G. T., CARRAZANA E. J., CHARNESSE M. E. Unilateral oculomotor palsy and bilateral ptosis from paramedian midbrain infarction. *Arch. Neurol.*, 1991, **48** : 983-986.
- NIGHOGHOSSIAN N., VIGHETTO A., TROUILLAS P. Nuclear oculomotor nerve syndrome and ocular tilt reaction caused by mesencephalic hematoma. *Rev. Neurol.*, 1991, **147** : 676-679.
- SAEKI N., YAMAURA A., SUNAMI K. Bilateral ptosis with pupil sparing because of a discrete midbrain lesion : Magnetic resonance imaging evidence of topographic arrangement within the oculomotor nerve. *J. Neuro-Ophthalmology*, 2000, **20** : 130-134.
- SAND J. J., BILLER J., CORBETT J. J., ADAMS H. P., DUNN V. Partial dorsal mesencephalic hemorrhages : Report of three cases. *Neurology*, 1986, **36** : 529-533.
- STERN L. Z., BERNICK C. Spontaneous, isolated, mesencephalic hemorrhage. *Neurology*, 1986, **36** : 1627.
- WARWICK R. Representation of the extraocular muscles in the oculomotor nuclei of the monkey : *J. Comp. Neurol.*, 1953, **98** : 449-495.
- WEISBERG L. A. Mesencephalic hemorrhages : Clinical and computed tomographic correlations. *Neurology*, 1986, **36** : 713-716.

C. T. IŞIKAY
 İbni Sina Hastanesi,
 Nöroloji Anabilim Dalı, 06100,
 Ankara, Turkey.
 isikay2@hotmail.com