

Axillary injection of botulinum A toxin in a patient with muscle cramps associated with severe axillary hyperhidrosis

Massimiliano FILOSTO¹, Laura BERTOLASI¹, Emiliana FINCATI¹, Alberto PRIORI², Giuliano TOMELLERI¹, Giancarlo CHIEREGATO³ and Nicolò RIZZUTO¹

¹Department of Neurological Sciences and Vision, Section of Clinical Neurology, University of Verona, Italy ; ²Institute of Neurology, University of Milan, IRCCS Ospedale Maggiore, Milan, Italy and IRCCS S. Giovanni di DIO-Fatebenefratelli Center, Brescia, Italy ; ³Institute of Dermatology, University of Verona, Italy

Abstract

Muscle cramps may be caused by fluid and salt loss induced by diffuse or focal hyperhidrosis. Recent reports have described the efficacy of botulinum toxin in the treatment of primary focal hyperhidrosis. Botulinum toxin inhibits sweating by blocking exocytosis of acetylcholine from presynaptic cholinergic nerve terminals.

We report the case of a patient who complained of frequent muscle cramps associated with unusually severe axillary hyperhidrosis. We used botulinum toxin to treat the excessive focal sweating presuming that it would also reduce the muscle cramps. A total dose of 200 MU of botulinum A toxin (Dysport) per axilla markedly reduced sweating and cramps. The beneficial effect started four days after the injection and it was still present five months later. Treatment was repeated in the sixth month with analogous results. No side-effects were observed and no compensatory sweating occurred.

Key words : Cramps ; axillary hyperhidrosis ; botulinum toxin.

affected patients severe social and psychological problems ; conventional medical or surgical treatments produce only a partial benefit or are associated with potentially serious side effects (Malone *et al.*, 1986 ; Byrne *et al.*, 1990 ; Freeman *et al.* 1992 ; Drott *et al.*, 1995 ; Bushara *et al.* 1996).

Recently, several reports have shown the efficacy of botulinum toxin in the treatment of palmar and axillary hyperhidrosis (Schinder *et al.* 1996 ; Naumann *et al.*, 1997 ; Schinder *et al.*, 1997 ; Shelley *et al.*, 1998 ; Naumann *et al.*, 1998 ; Odderson, 1998 ; Heckmann *et al.*, 2001). Botulinum toxin owes its successful use in the treatment of this condition to its blocking action of sympathetic postganglionic fibers to sweat glands (Bushara and Park, 1994).

In this study, we report a patient who complained of diffuse muscle cramps and severe axillary hyperhidrosis treated with botulinum toxin.

Patient and methods

An otherwise healthy 45-year-old woman complained of frequent diffuse muscle cramps, particularly of the foot, calf and intercostal muscles. The cramps occurred predominantly at night and mostly during hot weather and after profuse sweating.

Since childhood, the patient had also suffered from severe axillary hyperhidrosis that obliged her to change her clothes several times a day.

She had no hyperhidrosis of the palms or soles. Neither did she have other signs or symptoms of autonomic dysfunction. No electrolytic imbalance was present in routine blood tests. In the past, she used conventional treatments (topical aluminum chloride) with no benefit.

Neurological examination was normal. Electromyography, electroneurography, and sympathetic skin responses from upper and lower limbs were normal.

Before botulinum toxin treatment, we identified the hyperhidrotic areas with the alizarin red test

Introduction

Muscle cramps are common symptoms of neuromuscular disorders and are caused mostly by hyperactivity of the peripheral or central nervous system (Bertolasi *et al.*, 1993 ; Layzer, 1994). The major causes of muscle cramps are lower motoneuron diseases, radiculopathies, metabolic disorders (i.e., hypothyroidism and hypoadrenalism) and extracellular volume depletion after diarrhea, vomiting, diuretic therapy and hemodialysis. An additional cause of cramps is the acute fluid and salt loss through excessive sweating (i.e., primary hyperhidrosis), probably owing to the increased mechanical effect of muscle fibers on the nerve terminals in a contracted extracellular space (Layzer, 1994). Primary hyperhidrosis is a disorder that generally involves the palms, soles or axillas. Its prevalence is 0.6 to 1.0% in young adults (Adar *et al.*, 1977). It is an annoying complaint and causes

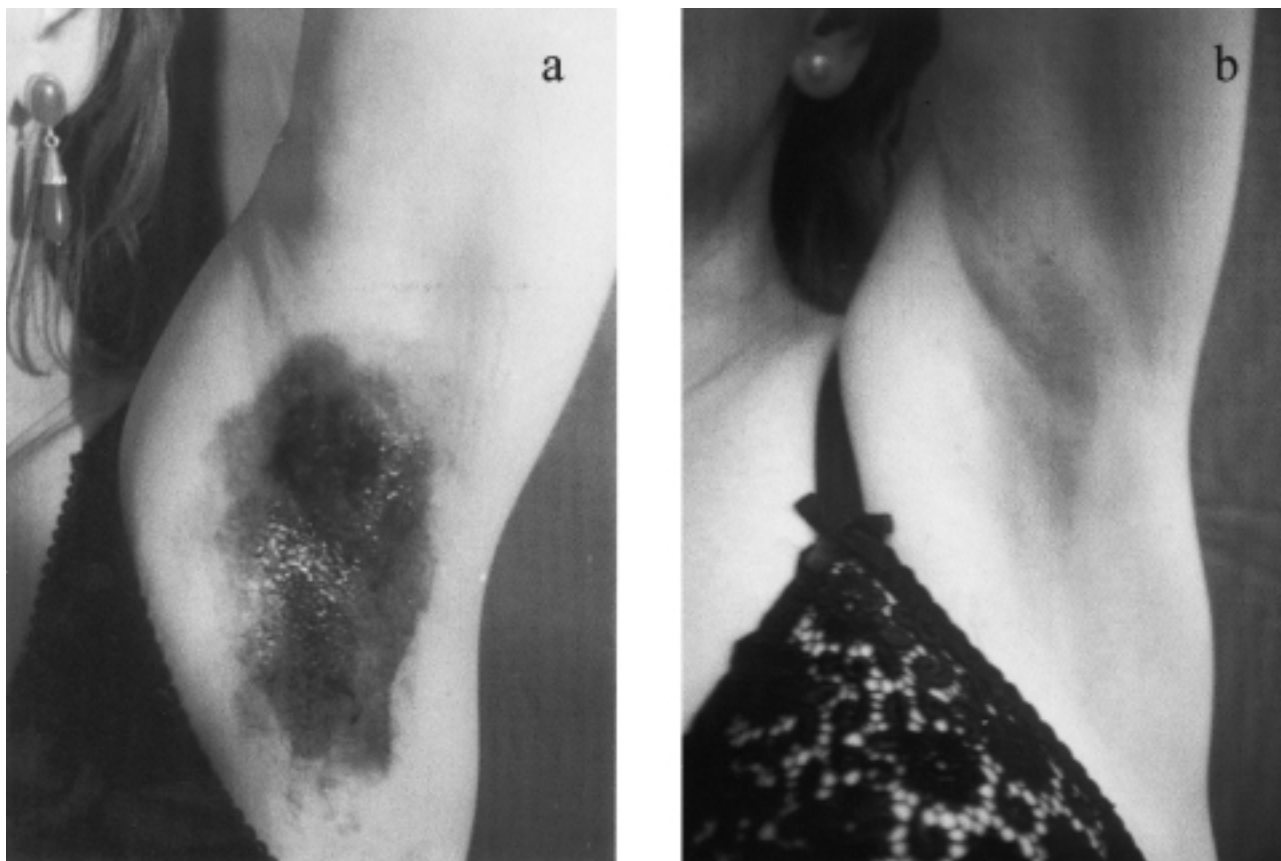


FIG. 1. — Axillary sweating documented by alizarin red test. A : Hyperhidrosis in the untreated left axilla. B : Evident sweating reduction in the left axilla two weeks after the botulinum toxin injections.

using a compound containing alizarin red powder 25 g, rice starch 50 g, and dehydrated sodium carbonate 25 g. This formula produces an exceedingly volatile substance and does not adhere to dry skin but, when painted onto sweated skin, adheres readily and changes to an intense violet color.

A total dose of 200 MU (mouse unit) of botulinum A toxin (Dysport, Ipsen), diluted with 0.5 ml of sterile saline solution, was injected subdermally into the right axilla in ten different sites (20 MU per site), using a 0.33 mm gauge needle, after informed written consent from the patient and ethical committee approval. We injected low single doses of botulinum toxin (20 MU) diluted in 0.5 cc of saline solution instead of one cc as recommended by suppliers to distribute the toxin more uniformly in the area of excessive sweating without unnecessary spread to the surrounding regions. After one week, the left axilla was treated similarly.

Six months later, an analogous treatment was repeated in both axillae.

In the period following the treatment, the patient did not use drugs or change her way of life.

Results

Four days after receiving the first botulinum toxin injection, the patient noted that excessive sweating in the right axilla had already diminished.

At the same time, the muscle cramps became less severe.

Two weeks after the treatment, the alizarin red test showed a marked reduction in sweating in most areas of the right axilla; only one small area (2 mm × 3 mm) of excessive sweating remained in a linear medial region. The patient no longer complained of muscle cramps.

Further assessment two weeks after injection of the left axilla again showed markedly reduced sweating (Fig. 1); the beneficial effect in the right axilla persisted and muscle cramps disappeared.

Botulinum toxin effect on sweating and muscle cramps was still present five months after the first injection. In the sixth month, the patient referred a slow and progressive reappearance of the hyperhidrosis which, later, became as severe as before treatment and was again associated with muscle cramps. At the end of the sixth month, we repeated botulinum toxin administration as previously described; results analogous to the first treatment were obtained.

No side-effects were reported. No compensatory sweating occurred.

Discussion

This report shows that muscle cramps associated with axillary hyperhidrosis can be effectively,

safely and persistently controlled by the local treatment of hyperhidrosis with botulinum toxin A. The treatment of severe benign muscle cramps is often difficult because systemic drugs may cause ill tolerated side-effects. A recent report has described successful treatment of muscle cramps by a neuromuscular block produced by local injection of botulinum toxin into the cramping muscle (Bertolasi *et al.*, 1997). In our study, we now show that botulinum toxin is also effective in treating muscle cramps secondary to hyperhidrosis by blocking the excessive sweating. In explaining why the muscle cramps disappeared, we think a direct reduction by spread of botulinum toxin through the bloodstream unlikely. Indeed, in a preceding study, after injection of botulinum toxin into the calf muscles of patients who had a benign cramp-fasciculation syndrome, the cramps on the treated side disappeared but the cramps on the untreated side remained (Bertolasi *et al.*, 1997). Furthermore, the patient we now describe never had muscle weakness or other side effects linked to the action of botulinum toxin on motor endplates.

In conclusion, our case confirms that acute fluid and salt loss may cause muscle cramps and suggests that botulinum toxin, although it needs repeated administration over time (every five months), may be effective in treating primary axillary hyperhidrosis and may also resolve the co-existing muscle cramps.

REFERENCES

- ADAR R., KURCHIN A., ZWEIG A., MOZES M. Palmar hyperhidrosis and its surgical treatment : a report of 100 cases. *Ann. Surg.*, 1977, **186** : 34-41.
- BERTOLASI L., DE GRANDIS D., BONGIOVANNI G., ZANETTE G. P., GASPERINI M. The influence of muscular lengthening on cramps. *Ann. Neurol.*, 1993, **33** : 176-180.
- BERTOLASI L., PRIORI A., TOMELLERI G., BONGIOVANNI L. G., FINCATI E. *et al.* Botulinum toxin treatment of muscle cramps : a clinical and neurophysiological study. *Ann. Neurol.*, 1997, **41** : 181-186.
- BYRNE J., WALSH T. N., HEDERMAN W. P. Endoscopic transthoracic electrocautery of the sympathetic chain for palmar and axillary hyperhidrosis. *Br. J. Surg.*, 1990, **77** : 1046-1049.
- BUSHARA K. O., PARK D. M. Botulinum toxin and sweating. *J. Neurol. Neurosurg. Psychiatry*, 1994, **57** : 1437-1438.
- BUSHARA K. O., PARK D. M., JONES J. C., SCHUTTA M. S. Botulinum toxin. A possible new treatment for axillary hyperhidrosis. *Clin. Exp. Dermatol.*, 1996, **21** : 276-278.
- DROTT C., GOTHBERG G., CLAES G. Endoscopic transthoracic sympathectomy : an efficient and safe method for the treatment of hyperhidrosis. *J. Am. Acad. Dermatol.*, 1995, **33** : 78-81.
- FREEMAN R., WALDORF H. A., DOVER J. S. Autonomic Neurodermatology (part II) : disorders of sweating and flushing. *Semin. Neurol.*, 1992, **12** : 394-407.
- HECKMANN M., CEBALLOS-BAUMANN A. O., PLEWIG G. Botulinum Toxin A for axillary hyperhidrosis (Excessive sweating). *N. Engl. J. Med.*, 2001, **344** : 488-493.
- LAYZER R. B. Muscle Pain, cramps and fatigue. In : *Myology*. ENGEL A. G., FRANZINI-ARMSTRONG C. (eds.). USA, McGraw-Hill, 1994, 1754-1768.
- LAYZER R. B. The origin of muscle fasciculation and cramps. *Muscle Nerve*, 1994, **17** : 1243-1249.
- MALONE P. S., CAMERON A. E. P., RENNIE J. A. The surgical treatment of upper limb hyperhidrosis. *Brit. J. Dermatol.*, 1986, **115** : 81-84.
- NAUMANN M., FLACHENECKER P., BROCKER E., TOYKA K., REINERS K. Botulinum toxin for palmar hyperhidrosis. *Lancet*, 1997, 9056 : 953.
- NAUMANN M., HOFFMANN V., BERGMANN I., HAMM H., TOYKA K. V. *et al.* Focal hyperhidrosis : effective treatment with intracutaneous botulinum toxin. *Arch. Dermatol.*, 1998, **134** : 301-304.
- ODDERSON I. R. Axillary hyperhidrosis : treatment with botulinum toxin A. *Arch. Phys. Med. Rehab.*, 1998, **79** : 350-352.
- SCHINDER P., BINDER M., BERGER T., AUFF E. Botulinum toxin injection in focal hyperhidrosis. *Brit. J. Dermatol.*, 1996, **134** : 1160-1161.
- SCHINDER P., BINDER M., AUFF E., KITTLER H., BERGER T. *et al.* Double-blind trial of botulinum A toxin for the treatment of focal hyperhidrosis of the palms. *Brit. J. Dermatol.*, 1997, **136** : 548-552.
- SCHINDER P., BINDER M., KITTLER H., STEINHOFF N., AUFF E. Uses of botulinum toxin. *Lancet*, 1997, 349, 9056 : 953.
- SHELLEY W. B., TALANIN N. Y., SHELLEY E. D. Botulinum toxin therapy for palmar hyperhidrosis. *J. Am. Acad. Dermatol.*, 1998, **38** : 227-229.

Laura BERTOLASI,
Department of Neurological Sciences and Vision,
Section of Clinical Neurology,
University of Verona,
P.le L.A. Scuro 10, 37134 Verona, Italy.