

Cyclosporine-A induced neurotoxicity after renal transplantation

Ulver DERICI¹, Turgay ARINSOY², Sukru SINDEL³, Turgut TALİ⁴, Alev LEVENTOGLU⁵ and Sevki SERT⁶

¹Department of Nephrology, ²Department of Nephrology, ³Department of Nephrology, ⁴Department of Radiology, ⁵Department of Neurology, ⁶Department of Nephrology, Gazi University Hospital, Ankara, Turkey

Abstract

Cyclosporine-A is a highly potent immunosuppressive agent for solid organ transplantation, but has many side effects including nephrotoxicity, hypertension, gum hyperplasia, hepatotoxicity, and neurotoxicity. Neurotoxicity is a less known toxic effect. The pathogenesis of this effect is unclear. However, it has been postulated that hypomagnesemia, hypocholesterolemia, corticosteroids, and/or neurotoxic substances can induce this syndrome. Also, it has been suggested that the endothelial damage caused by Cyclosporine-A may contribute to neuropeptide-mediated ischemia in the brain and lead to the development of neurological symptoms. In this report, we present a case with reversible neurologic deficits whose symptoms returned to normal after the cessation of cyclosporine-A.

Key words : Renal transplantation ; cyclosporine A ; neurotoxicity ; MRI.

Introduction

Cyclosporine-A (CsA), a highly potent immunosuppressive agent for solid organ transplantation, has many side effects including nephrotoxicity, hypertension, hypertrichosis, gum hyperplasia, infections, hyperkalemia, hypomagnesemia, increased risk of certain cancers, and neurotoxicity. Neurotoxicity is a less known toxic effect and presents with a wide range of clinical symptoms including mental status changes, tremor, ataxia, paraparesis, peripheral neuropathy, cerebellar symptoms, parkinson syndrome, somnolence, visual disturbance, cortical blindness, vestibular-cochlear toxicity, seizures, and coma (Palmer and Toto, 1991 ; Erer *et al.*, 1996). These side effects have particularly been reported after liver, bone marrow, kidney and rarely after heart transplantation (Palmer and Toto, 1991 ; McManus *et al.*, 1992 ; Drachman *et al.*, 1996 ; Erer *et al.*, 1996 ; Esterl *et al.*, 1996). Central nervous system (CNS) side effects of CsA have been reported to occur in up to 42% of patients (Idilman *et al.*, 1998). However, the majority of these reports has been obtained from studies in bone marrow and liver

transplant recipients (Palmer and Toto, 1991, Gijtenbeek *et al.*, 1999). There are few reports about CsA-induced neurotoxicity after kidney transplantation (Palmer and Toto, 1991). CNS toxicity may be reversible after withdrawal or temporary reduction of CsA. Although the pathogenesis of neurotoxicity is unclear, it has been postulated that neuropeptide-mediated ischemia, corticosteroids, hypomagnesemia, hypocholesterolemia, and/or neurotoxic substances could induce this syndrome. In this report, a renal transplant patient with CsA induced neurotoxicity is presented.

Case Report

A fifty-year-old female patient who was on hemodialysis for the last seven years presented for cadaveric renal transplantation. She had an uneventful surgery and early postoperative period. For the first postoperative 10 days, she received anti-thymocyte globulin (ATG-Fresenius, 3 mg/kg per day), azathioprine (AZA, 2 mg/kg per day) and prednisolone (P, 0.5 mg/kg per day). On day 10, ATG was switched to CsA at a dose of 5 mg/kg/day. On postoperative day 20, she complained of headache, tinnitus, visual disturbance, and tremor. Within 24 hours, her mental status deteriorated and somnolence developed. Her vital signs were normal. Serum creatinine level was 132.6 µmol/L (normal : 53-133 µmol/L), blood urea nitrogen (BUN) was 7.8 mmol/L (normal : 2.9-8.9 mmol/L), and serum bilirubin, magnesium and other electrolytes were within normal limits. Plasma CsA level was 287.02 ng/ml (normal : 150-500 ng/ml). Serum cholesterol level was 5.14 mmol/l (normal : < 5.18 mmol/l). Lumbar puncture was unremarkable. Serologic examinations for Cytomegalovirus, Epstein-Barr virus, Herpes simplex virus, Cryptococcus and Toxoplasma were negative. Over the next 24 hours, the patient suffered a generalized seizure that was terminated by intravenous diazepam. Electroencephalography disclosed diffuse slow wave abnormalities without epileptiform activity. Computed tomography (CT) of the brain revealed patchy, heterogeneous hypo-

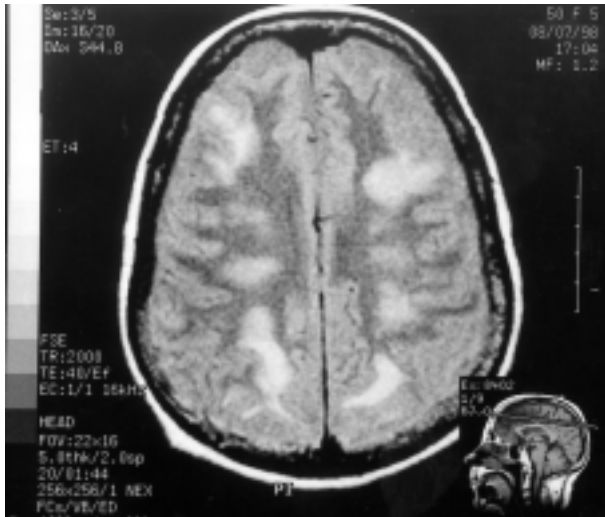


FIG. 1. — Axial proton density weighted images demonstrate patchy areas of heterogeneous hyperintensity located in the centrum semiovale and periventricular white matter. These lesions coalesce and show extension to the subcortical area. There is neither effacement of the sulci nor signal change of neighbouring cortex.

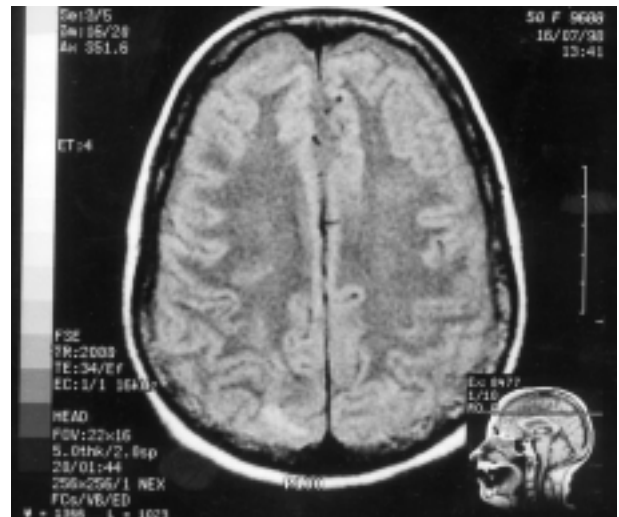

FIG. 2. — Axial proton density weighted images of follow-up MRI demonstrate obvious improvement of the lesions. There are only two small areas located in the bilateral parietal subcortical area, which is not seen on computed tomography image (not illustrated).

dense lesions that extended to the subcortical areas located in the parietal and frontal white matter bilaterally (not illustrated). Axial proton density weighted images of Magnetic Resonance Imaging (MRI) demonstrated heterogeneous hyperintense patchy areas in the centrum semiovale as well as periventricular white matter. These lesions with well-defined borders coalesced and showed extension to the subcortical area. (Figure 1). CsA therapy was discontinued because no other cause could be identified for change in mental state. In addition, mannitol, dexamethasone and epidantoin treatments were started for brain edema. Her clinical status improved gradually. A follow-up MRI of the brain was performed 8 days after CsA cessation. MRI revealed marked improvement of the described lesions (Figure 2), and antiedema therapy was discontinued. CsA therapy was started at a dose of 2 mg/kg/day. Reinstitution of CsA therapy at a lower dose did not result in any neurological symptoms. During the follow-up, plasma CsA levels were maintained lower than the usual limits. At present, the patient is on the triple drug therapy (CsA-AZA-P) for one year. Her renal functions are within normal range and she remains free of neurological symptoms.

Discussion

CNS toxicity is a not a well understood side effect of CsA. Erer *et al.* (1996) examined this toxicity by separating three categories as a grade 1, 2 and 3. Grade 1 neurotoxicity includes mental status changes, tremor, headache; grade 2 includes visual disturbance, cortical blindness; grade 3 includes seizures and coma. Seizures have been reported to

occur in 1.8% of renal transplant patients, 5.5% of bone marrow, and 25% of liver transplant recipients (Palmer and Toto, 1991). We initially observed grade 1 neurotoxicity in our patient, but symptoms progressed to grade 3. The mechanism of CsA-induced neurotoxicity still remains unknown. It has been suggested that intravenous administration and high levels of CsA may contribute to the drug-associated neurotoxicity. However, neurotoxicity can also be observed after oral CsA therapy with normal serum CsA levels (Menegaux *et al.*, 1994; Mueller *et al.*, 1994). Also, inhibitors of cytochrome P-450 such as methylprednisolone increase CsA levels, but neurotoxicity due to CsA can occur at normal and at high drug levels (Gijtenbeek *et al.* 1999). On the other hand, the degree of neurotoxicity is also not always related to the plasma level of cyclosporine (Debaere *et al.*, 1999). Our patient was also shown neurotoxicity after oral CsA therapy, although the drug levels were normal. Toxicity has frequently been observed in organs such as brain, kidney, and liver that maintain high cyclophilin concentrations (Ryffel *et al.*, 1991; Mueller *et al.*, 1994). According to this view, it is believed that there is a correlation between tissue cyclophilin concentrations (CsA-binding protein) and toxicity. On the other hand, hypocholesterolemia, magnesium deficiency, neurotoxic substances, hypertension, and aluminium overload may induce neurotoxicity or may play a contributory role (Borland *et al.* 1985; Palmer and Toto, 1991; McManus *et al.* 1992; Menegaux *et al.*, 1994; Mueller *et al.*, 1994). Also, significant correlation between neurotoxicity and hypocholesterolemia has been shown (Mueller *et al.*, 1994). When total cholesterol or low density

lipoprotein levels are low, up-regulation of the low density lipoprotein receptor occurs. Since intracellular transport of cyclosporine is also via these low density lipoprotein receptors, upregulation of these receptors leads to the increased tissue levels of CsA (McManus *et al.*, 1992). In addition, a relationship between hypomagnesemia and seizures has been described (Thompson *et al.*, 1984). The increase of neurotoxic substances, such as bilirubin, BUN, or ammonia, has also been thought to correlate with CNS toxicity (Mueller *et al.*, 1994). In our case, we observed neither hypocholesterolemia, hypomagnesemia nor the increase of neurotoxic substances, and hypertension.

A reversible posterior leukoencephalopathy syndrome (PLE) is the most serious CsA-induced neurological side effect. This syndrome is characterized by headache, altered mental functioning, seizures, and cortical blindness associated with multifocal, bilateral white matter abnormalities on imaging studies indicating leukoencephalopathy predominantly in the posterior regions (parieto-occipital and temporal lobes) of the cerebral hemispheres and also pons, thalamus, and cerebellum (Gijtenbeek *et al.*, 1999). Most of the patients with this syndrome have hypertension, high CsA levels, hypocholesterolemia, and hypomagnesemia. Neurological signs have regressed after the treatment of hypertension or reduction or withdrawal of CsA (Gijtenbeek *et al.*, 1999). In our patient, clinical findings were similar to PLE although hypertension, high CsA levels, hypocholesterolemia, and hypomagnesemia were absent. The location of white matter abnormalities on MRI was similar to the affected areas in PLE and all findings reversed after withdrawal of CsA in this patient. Therefore, neurological findings of our patient could be PLE.

A previous theory about the mechanism of neurotoxicity includes neuropeptide-mediated ischemia (Corey *et al.*, 1999). CsA is known to cause the release of potent vasoconstrictors such as endothelin-1 and thromboxane A₂ by affecting the vascular endothelium. Endothelin-1 causes similar vasoconstriction and vasospasm in cerebral vessels, initiating mild, reversible ischemia and white matter edema. The endothelial damage caused by CsA also may be accompanied by the release of cytokines which may further contribute to vascular injury and disruption of the blood-brain barrier (Corey *et al.*, 1999). This endothelial damage can also cause thrombotic microangiopathy associated with neurological complications (Gijtenbeek *et al.*, 1999). A recent hypothesis regarding the mechanism of neurotoxicity is the high-pressure failure of cerebral autoregulation. In CsA neurotoxicity, predominantly the posterior regions of the brain are involved because of fewer adrenergic receptors in vertebrobasilar system and its branches. It has been proposed that perivascular sympathetic nerves are stimulated by hypertension associated with CsA,

resulting in increased vascular resistance protecting the brain from marked increases in intravascular pressure. However, the deficiency of these receptors in the posterior regions may lead to increased perfusion and disturbance of cerebral autoregulation, disruption of the blood-brain barrier, and passive extravasation of fluid into the interstitium (vasogenic edema) (Gijtenbeek *et al.*, 1999 ; Coley *et al.*, 1999). Especially, the newer MRI techniques (Fluid attenuated inversion recovery MRI and diffusion-weighted MRI) are of particular value in the clinical management of CsA-induced cerebral edema. Diffusion-weighted imaging provides valuable information to make a differential diagnosis between ischemic cytotoxic edema and interstitial edema. Therefore, it can determine whether CsA-related neurotoxicity is caused by ischemia or failure of cerebral autoregulation (Corey *et al.*, 1999).

CT and particularly MRI are both useful techniques in evaluating the radiological abnormalities in patients with CsA neurotoxicity. MRI can disclose lesions when the CT scan is normal. Although the clinical presentation of CsA-induced neurotoxicity is diverse, the pattern of radiological abnormalities is relatively characteristic. MRI shows signal changes within the cerebral cortex and juxtacortical white matter of the occipital lobes, posterior temporal, parietal, and frontal lobes (Corey *et al.*, 1999). In our case, the pathological findings were located in the parietal and frontal white matter bilaterally, which were demonstrated by both CT and MRI. These pathological findings rapidly disappeared with cessation of CsA therapy. Neither radiological changes nor neurological symptoms reappeared with a low dose of CsA during the 12 months treatment period.

In summary, the possibility of CsA-associated neurotoxicity should be kept in mind after renal transplantation. CT and particularly MRI are both useful techniques in evaluating the radiological abnormalities in these cases. The causes and contributory factors of the syndrome are unknown and further studies are needed to explain the mechanisms of CsA-related neurotoxicity.

REFERENCES

- BORLAND I. A., GOSNEY J. R., HILLIS A. N., WILLIAMSON E. P. M., SELLS R. A. Hypomanganesemia and cyclosporin toxicity. *Lancet*, 1985, **12** : 103-104.
- COLEY S. C., PORTER D. A., CALAMANTE F., CHONG W. K., CONNELLY A. Quantitative MR diffusion mapping and cyclosporine-induced neurotoxicity. *AJNR*, 1999, **20** : 1507-1510.
- DEBAERE C., STADNIK T., DE MAESENEER M., OSTEAUX M. Diffusion-weighted MRI in cyclosporin A neurotoxicity for the classification of cerebral edema. *Eur. Radiol.*, 1999, **9** : 1916-1918.
- DRACHMAN B. M., DENOFRIO D., ACKER M. A., GALETTA S., LOH E. Cortical blindness secondary to cyclosporine after orthotopic heart transplanta-

- tion : a case report and review of the literature. *J. Heart Lung Transplant*, 1996, **15** : 1158-1164.
- ERER B., POLCHI P., LUCARELLI G., ANGELUCCI E., BARONCIANI D. *et al.* CSA-associated neurotoxicity and ineffective prophylaxis with clonazepam in patients transplanted for thalassemia major : analysis of risk factors. *Bone Marrow Transplant.*, 1996, **18** : 157-162.
- ESTERL R. M., GUPTA N., GARVIN P. J. Permanent blindness after cyclosporine neurotoxicity in a kidney-pancreas transplant recipient. *Clin. Neuropharmacol.*, 1996, **19** : 259-266.
- GIJTENBEEK J. M. M., VAN DEN BENT M. J., VECHT C. J. Cyclosporine neurotoxicity : a review. *J. Neurol.*, 1999, **246** : 339-346.
- IDILMAN R., DE MARIA N., KUGELMAS M., COLANTONI A., VAN THIEL D. H. Immunosuppressive drug-induced leukoencephalopathy in patients with liver transplant. *Eur. J. Gastroenterol. Hepatol.*, 1998, **10** (5) : 433-6.
- McMANUS P. R., O'HAIR D. P., SCHWEIGER J., BEITZINGER J., SIEGEL R. Cyclosporine-associated central neurotoxicity after heart transplantation. *Ann. Thorac. Surg.*, 1992, **53** : 326-327.
- MENEGAUX F., KEEFFE E. B., ANDREWS B. T., EGAWA H., MONGE H. *et al.* Neurological complications of liver transplantation in adult versus pediatric patients. *Transplantation*, 1994, **58** : 447-50.
- MUELLER A. R., PLATZ K. P., BECHSTEIN W. O., SCHATTENFROH N., STOLTENBURG-DIDINGER G. *et al.* Neurotoxicity after orthotopic liver transplantation. A Comparison between cyclosporine and FK-506. *Transplantation*, 1994, **58** : 155-169.
- PALMER B. F., TOTO R. D. Severe neurologic toxicity induced by cyclosporine A in three renal transplant patients. *Am. J. Kidney Dis.*, 1991, **18** : 116-121.
- RYFFEL B., WOERLY G., GREINER B., HAENDLER B., MIHATSCH J. *et al.* Distribution of the cyclosporine binding protein cyclophilin in human tissues. *Immunology*, 1991, **72** : 399-404.
- THOMPSON C. B., JUNE C. H., SULLIVAN K. M., THOMAS E. D. Association between cyclosporin neurotoxicity and hypomagnesaemia. *Lancet*, 1984, **17** : 1116-1120.

U. DERICI, M.D.,
Gazi University Hospital,
Nephrology Department,
06510 Besevler, Ankara, Turkey.