

Letter to the Editor

Subacute Sclerosing Panencephalitis in a vaccinated, internationally adopted child

R. BROUNS^{1,2}, P. VERLINDE³, L. LAGAE³, J. DE KOSTER¹, F. LEMMENS¹ and W. VAN DE CASSEYE^{1,3}

¹Department of Pediatrics, ZOL, Genk, Belgium ; ²Department of Neurology, Catholic University of Leuven, Belgium ;

³Department of Pediatrics, Catholic University of Leuven, Belgium

Subacute sclerosing panencephalitis is a slowly progressive inflammatory and neurodegenerative disease caused by persistence of measles virus in the central nervous system. Progressive clonal dissemination of defective measles virus throughout the central nervous system with demyelination and neuronal death, caused both by host immune response and viral replication appears to be the core of the pathogenesis. Causal treatment for this inexorable disease remains controversial, but measles vaccination seems an effective means of preventing SSPE. Nevertheless, we present a case of SSPE in a vaccinated, internationally adopted child :

An 8.5-year-old girl was admitted to our hospital with mild tremor of the right hand and mouth for 3 months and occasional drop attacks. At school, the teacher noticed an altered writing pattern, diminished concentration, declining results, and changes in behaviour.

Clinical examination revealed increased osteo-tendinous reflexes in the right leg, dysarthria, perseveration, visuomotoric apraxia, and writing difficulties. Romberg's test was positive. We managed to observe the mild tremor described by the mother and we clearly saw myoclonic jerks of the mouth and neck together with eye deviation to the right.

The girl was born in the Philippines. Her Belgian parents adopted her in October 1992 at an age of 1 year and 2 months. There is little known about her first period of life except that she was hospitalised shortly before the adoption for a severe lung infection and failure to thrive. She received the essential vaccinations including vaccination against measles on 20 May 1992.

Although vaccination against measles virus was administered at 9 months of age, which is common in endemic areas, the diagnosis of SSPE was made based on the clinical presentation and disease progression, slow waves and diffuse delta-activity on EEG (Fig. 1) with periodic slow wave complexes time-locked to synchronous generalized myoclonic

jerks on video-EEG telemetry, hyperglobulinorachia (IgG : 134 mg/dl, IgG/albumin ratio : 1,7866) with oligoclonal bands of immunoglobulins and elevated IgG antibodies to measles virus in CSF (14000 mIU/ml, Boehringer ELISA processor) and in serum (34000 IU/ml, >325 IU/ml is positive).

The initial treatment with valproic acid showed no beneficial effect on the myoclonic jerks. Therapy therefore was changed to carbamazepine with temporary improvement. One month after diagnosis, isoprinosine (2000 mg/day) was added.

After a disease progression of seven months, the girl died quietly in a vegetative state.

Diagnosis of SSPE requires the presence of three of the following five criteria : 1) typical clinical presentation with inexorable cognitive decline and stereotyped myoclonic jerks ; 2) characteristic EEG ; 3) elevated CSF γ -globulin levels ; 4) elevated CSF measles antibodies ; 5) typical histopathological findings in brain biopsy or autopsy (Risk and Haddad, 1979).

Causal treatment for SSPE remains controversial. The most frequently used medication is isoprinosine (100 mg/kg/day orally), a purine derivative that combines antiviral properties against both RNA and DNA viruses with immunomodulating capacities by affecting lymphocyte and macrophage functions. Treatment with intraventricular, intrathecal, and possibly intravenous α -interferon (IFN) may be more effective but is known to cause important complications. The combination of isoprinosine and intraventricular α -IFN may act synergistically to produce temporary remission in 44% to 50% of treated patients, mainly when started in stage II or earlier and in patients with slow disease progression.

Due to large scale vaccination efforts, the incidence of measles and SSPE declined significantly in Western Europe and North America and is estimated to be less than one per million population. In other regions, where effective vaccination programs have not been established yet, measles con-

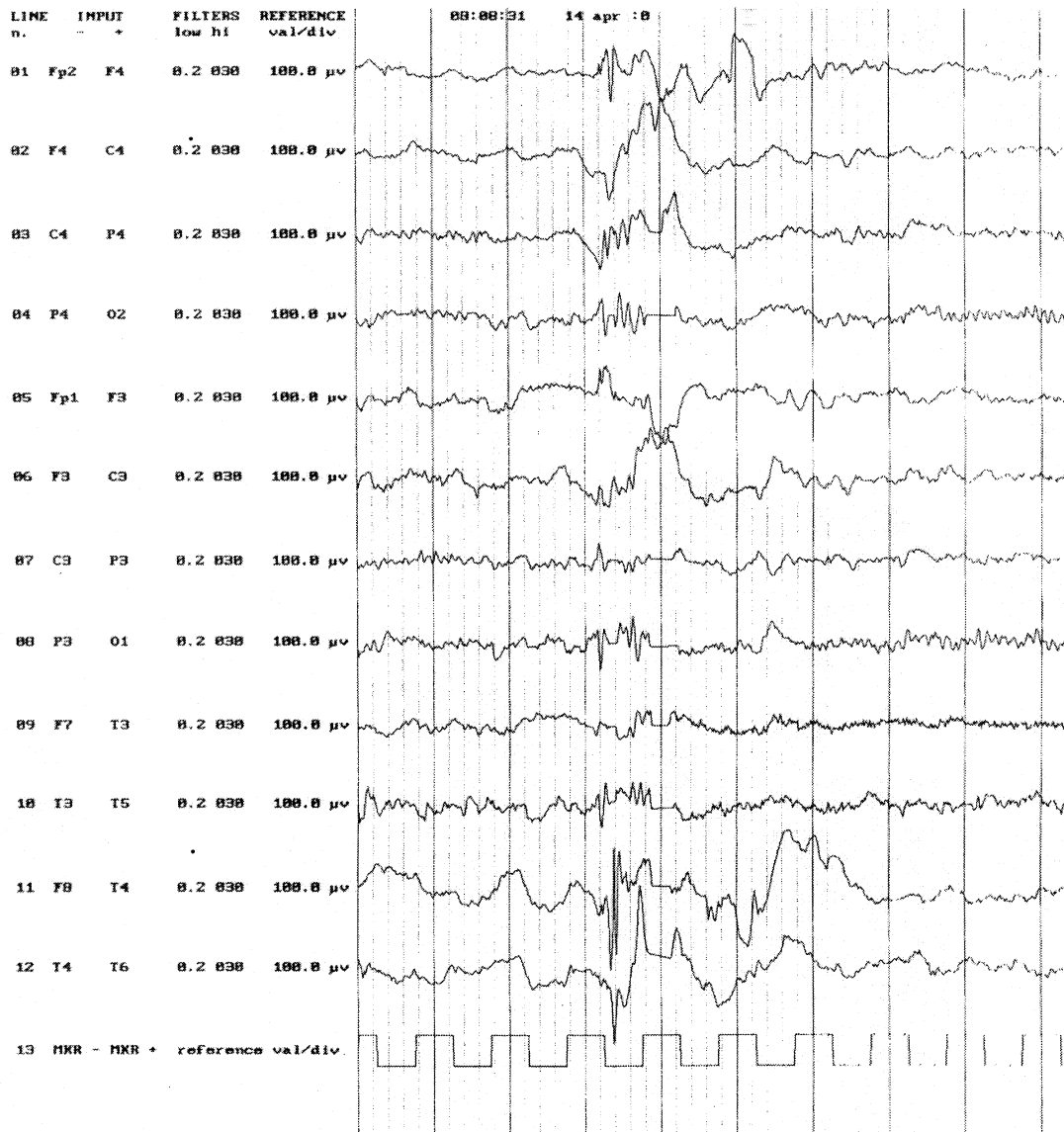


FIG. 1. — EEG : slow waves and diffuse delta-activity

tinues to be endemic and the incidence of SSPE ranges from 20 to 100 per million population. This indicates that measles vaccination not only is a safe means of preventing 90 million cases of measles globally each year, it is also an effective means of preventing SSPE (Beersma *et al.*, 1992).

SSPE in vaccinated individuals has been reported in the literature before. This is probably attributable to vaccine failure, not to the attenuated vaccine virus. Primary vaccine failure is often caused by interfering maternal antibodies at young age (Zhu *et al.*, 2000); therefore the routine age for vaccination is 15 months, except for endemic areas where vaccine is administered at 6 to 9 months (Hall *et al.*, 1990) as in the case we present. Other causes of vaccine failure include genetic drift of MV or import of genetically different MV strains. SSPE in an internationally adopted child has been described before (Bonthius *et al.*, 2000) and we believe that other cases of SSPE due to import will follow, even

in regions where MV is no longer endemic thanks to good control measures, until MV has been eradicated globally.

REFERENCES

- BEERSMA M. F. C., GALAMA J. M. D., VAN DRUTEN H. A. M., RENIER W. O., LUCAS C. J. *et al.* Subacute sclerosing panencephalitis in The Netherlands 1976-1990. *Int. J. Epidemiol.*, 1992, **21** : 583-88.
- BONTHIUS D. J., STANEK N., GROSE C. Subacute sclerosing panencephalitis, a measles complication, in an internationally adopted child. *Emerg. Infect. Dis.*, 2000, **6** : 377-381.
- HALL A. J., GREENWOOD B. M., WHITTLE H. Modern vaccines practice in developing countries. *Lancet*, 1990, **335** : 774-777.
- RISK W. S., HADDAD F. S. The variable natural history of subacute sclerosing panencephalitis. *Arch. Neurol.*, 1979, **36** : 610-614.

ZHU Y., ROTA P., WYATT L., TAMIN A., ROZENBLATT S.
Evaluation of recombinant vaccinia virus –
measles vaccines in infant rhesus macaques with
preexisting measles antibody. *Virology*, 2000,
276 : 202-213.

Raf BROUNS,
University Hospital Gasthuisberg,
Department of Neurology,
Herestraat 49,
B-3000 Leuven (Belgium).