

## Original article

## De novo cryptogenic refractory multifocal febrile status epilepticus in the young adult : a review of six cases

I. VAN LIERDE<sup>1</sup>, W. VAN PAESSCHEN<sup>1</sup>, P. DUPONT<sup>2</sup>, A. MAES<sup>2</sup>, R. SCIOT<sup>3</sup>Departments of Neurology<sup>1</sup>, Nuclear Medicine<sup>2</sup> and Neuropathology<sup>3</sup>, University Hospital Gasthuisberg, Katholieke Universiteit Leuven, Belgium

### Abstract

*Background :* Status epilepticus (SE) is a common neurological emergency. In around 10 percent, the etiology of SE is not clear, i.e. cryptogenic SE.

*Aim :* To describe six young adult patients with de novo cryptogenic multifocal febrile SE with poor outcome.

*Methods :* Retrospective chart review.

*Results :* We describe six patients who presented with de novo SE. All were young adults with an unremarkable previous medical history. In all except one, the family history for epilepsy was negative. All had a febrile illness in the week preceding SE. Investigations were unable to reveal the underlying etiology. SE proved refractory to conventional antiepileptic drug treatment (AED) and anesthesia was required to control seizures. Seizures during SE or ensuing epilepsy were multifocal. Brain pathology in four patients was normal in two and showed changes secondary to seizures in two. Outcome was poor in all cases : one patient died during the course of SE, another patient remained with severe mental and physical disability as well as refractory epileptic seizures, the other four developed refractory multifocal epilepsy. One of these patients died a sudden unexpected death in epilepsy (SUDEP) and one drowned during a seizure.

*Conclusions :* Six patients were reviewed who presented with de novo cryptogenic multifocal refractory febrile SE. The possible etiologies are discussed. Based on the similarities in these cases, a distinct refractory SE syndrome might be assumed. Further prospective studies will, however, be required to validate this hypothesis as well as to elucidate its etiology and optimize treatment.

*Key words :* Status epilepticus ; refractory ; multifocal ; cryptogenic ; febrile.

### Introduction

Status epilepticus (SE) is a common, potentially life-threatening neurological condition, affecting approximately 10-20 patients per 100 000 population annually (1, 2). SE is defined as a seizure that persists for a sufficient length of time or repeated seizures without recovery between attacks (3). Recently, five minutes of continuous seizures has been proposed as a working definition of SE (4).

Mortality in SE ranges between 15-22% and is associated with the duration of seizure activity, age and underlying etiology (5). Sequelae of SE include epileptic brain damage, neurological and cognitive deficits and epilepsy, the latter comprising a risk of approximately 40% in contrast to 10% after a first single seizure (6).

SE can be classified as acute symptomatic or unprovoked. SE is considered unprovoked in the absence of an identified acute insult, and is further categorized as progressive symptomatic, remote symptomatic or idiopathic/cryptogenic. The idiopathic or cryptogenic group refers to SE without an identified acute precipitating factor or history of prior neurological insult (2).

The aim of this report is to present the clinical history of six young adult patients who presented with de novo cryptogenic multifocal febrile SE with poor outcome and to review the current literature on this subject.

### Patients and Methods

Charts of six patients -presenting between 1988 and 2001- were reviewed retrospectively. These patients were chosen because of following similarities in their history : 1. refractory SE (defined as seizures lasting sixty to ninety minutes despite conventional AED (7)), 2. absence of prior neurologic illness, 3. preceding febrile illness, 4. unidentified etiology despite thorough investigation, 5. multifocality in SE or ensuing epilepsy, 6. poor outcome. Four patients were admitted for SE to our hospital. One patient, who underwent a presurgical evaluation in our hospital, was admitted to another hospital for the episode of SE. Another patient did not present to our hospital ; her case was briefly described previously (8). The following data were collected when available : demographics, past medical as well as family history, illnesses preceding SE, seizure description of SE, investigations during the hospitalization for SE (hematology, chemistry, CSF studies, microbiological studies including serology and cultures, EEG, imaging [CT, MRI, SPECT, PET], pathology), treatment of SE, and outcome (description and frequency of seizures of the

ensuing epilepsy, investigations for epilepsy including EEG, imaging studies, video-EEG, treatment of epilepsy, psycho-social outcome).

Eight-channel EEG's were performed during SE. After SE sixteen-channel EEG's were performed as part of follow-up. In two patients continuous EEG-monitoring was obtained during SE by means of a four-channel EEG-monitor with electrodes over the frontal lobes F7, F8, FP1 and FP2 (patient 5 and 6). Three of our patients underwent video-EEG registration in the years following SE as part of a presurgical evaluation (patient 1-3) (Table 2).

A fluorodeoxyglucose (FDG)- PET during SE was performed in two of our patients. The images of one of these patients (patient 5) are included (Fig. 1). The PET scans were performed during a trial to discontinue propofol during EEG-monitoring. Since both patients had ictal activity during the FDG-uptake, we considered these scans to be ictal studies. Propofol was discontinued twenty minutes before FDG injection, and restarted thirty minutes afterwards. These FDG images were acquired on a CTI-Siemens ECAT EXACT HR+.

The FDG image was co-registered with a surface-rendered 3D- MRI scan of the brain. The co-registered FDG image was thresholded at 50% of its maximum to show all areas of hypermetabolism.

In four of our patients pathology was obtained. In two cases this consisted of an autopsy (patient 4 and 6). In one case the autopsy was not performed at our hospital (patient 4). In the two other cases (patient 2 and 5) a brain biopsy was performed at our hospital. For the histological analysis, tissue fragments were fixed in 6% formaldehyde and processed in paraffin. Five micron thick paraffin sections were stained with hematoxylin and eosin. In addition immunoperoxidase stains were performed using monoclonal antibodies against neurofilaments, synaptophysin and glial fibrillary acidic protein (GFAP).

## Results

Six young adult patients (four women) with a median age of 23 years (range : 18-30) were admitted to hospital with SE (Table 1). None had a previous medical history of note and none had a history of epilepsy or febrile seizures. All had experienced a febrile illness in the week prior to admission, and most had visited their general practitioner because of this. All presented with serial complex partial seizures with and without secondary generalization, without full recovery of consciousness between seizures.

Examination of CSF revealed a mild lymphocytic pleocytosis (with a maximum of 28 cells), except in one case (patient 5) where polymorphonuclear predominance was found and another case with a normal leucocyte count (patient 3). Serum

and CSF viral serology and cultures, including screening for Herpes Simplex virus, remained negative (Table 1). There was no evidence of intoxication in any of our patients.

Initial high-resolution MRI of the brain was normal, though transient meningeal enhancement was seen in two patients (patients 2 and 5).

Since meningo-encephalitis was the prime differential diagnosis, all were initially treated with IV acyclovir and antibiotics.

SE was refractory to standard IV AED treatment. General anesthesia was used in five patients for a median of 32 days (range : 1-191). Thiopental was used in five, propofol and midazolam in two. Patient 4 was treated with IV chlormetiazole for 24 days. Mean duration of SE was 50 days (range : 6-191).

Plasma-exchange and high dose corticosteroids were administered in two patients (patient 5 and 6) without any benefit.

Seizures were multifocal during SE, subsequent epilepsy, or both (Table 2).

During SE, FDG-PET revealed multifocal areas of cortical hypermetabolism against a background of diffuse cortical hypometabolism in two patients (patient 5 and 6) (Fig. 1), consistent with multifocal ictal activity during FDG uptake. Clinical observations during SE suggested multifocal onset in one of these patients (patient 6). Multifocal seizure onset in patient 5 was not clinically suspected, since a history of different seizure types was not obtained and progression to subtle SE masked the motor expression of different seizure types.

In two patients multifocal seizure onset during SE could be suspected clinically from the retrospective chart review (patient 1 and 2). In the other two, multifocal seizure onset during SE was not clear. After recovery from the SE, these four patients (patients 1-4) developed refractory partial epilepsy, that was multifocal (EEG/clinical evidence in 4, video-EEG and subtraction ictal SPECT co-registered to MRI-evidence (SISCOM) in 1).

In two cases (patient 2 and 5) a brain biopsy was performed at our hospital. The place of the biopsy was guided by EEG and clinical findings in one patient (patient 2) and by SISCOM in the other (patient 5). Both biopsies showed normal findings.

General outcome was poor. One patient developed severe mental and physical disability, as well as refractory epilepsy and remained institutionalized (patient 5). One patient died during the course of SE (patient 6). None of the other four patients were able to return to their previous level of functioning due to frequent seizures, cognitive decline and associated psychiatric morbidity. Two patients (patient 3 and 4) died suddenly as a result of seizures (one sudden unexpected death in epilepsy (SUDEP), one accidental drowning during a seizure).

MRI several months after the SE demonstrated slight cortical and bilateral hippocampal atrophy in

Table 1

	Patient 1	Patient 2	Patient 3	Patient 4	Patient 5	Patient 6
Gender	M	F	M	F	F	F
Age (years)	24	30	22	18	19	26
Febrile illness	+	+	+	+	+	+
CSF (WBC, gluc, prot, HSV)	22 (Ly), gluc 94, prot 540, HSV-	13 (Ly), gluc 90, prot 443, HSV-	1, gluc 74, prot 520, HSV -	9 (Ly) HSV-	10 (Neu 72% Ly 25%), gluc 73, prot 427, HSV-	28 (Ly), gluc 87, prot 320, HSV-
Infectious screening (serum and/or CSF)	HSV ; Adenovirus ; Influenza A/B ; para-influenza 1-3 ; measles ; CMV ; VZV ; LCM ; coxsackie BI-3 ; poliomyelitis 1-3 ; EBV ; HIV	HSV ; Adenovirus ; mumps ; VZV ; chlamydia ; mycobacterium	HSV	HSV ; mycoplasma ; chlamydia ; Q-fever ; influenza A/B ; VZV ; mumps ; EBV ; borrelia ; treponema pallidum ; toxoplasma ; CMV ; brucella ; hepatitis A/B	HSV ; borrelia ; treponema pallidum ; hepatitis A/B	HSV ; mycoplasma ; lues ; borrelia ; cryptococcus ; toxoplasma ; CMV ; HIV ; EBV ; RSV ; influenza A/B
MRI initial	nl	meningeal enhancement	nl	NA	meningeal enhancement	nl
MRI Follow-up	nl	Cortical and bilat Hc atrophy	Cortical and bilat Hc atrophy	Progressive bilat HS	nl	NA
Pathology	NA	Brain biopsy : nl	NA	Autopsy : bilat HS	Brain biopsy : nl	Autopsy : bilat Hc neuronal loss, depletion cerebellar Purkinje cells
Treatment of status epilepticus	PB, PHT, THP, LZP, DZP	LZP, VPA, PHT, PB, LTG, THP	THP, PHT, VPA, PB, VGB, CLB	Chlormethiazole, PHT, VPA, DZP, CZP, CBZ, PB	PHT, VPA, LTG, TPM, prop, mid, THP, PB, TPM, LTG, LZP, CZP, GBP, VGB, TGB, LEV, CLB, pred, PE	DZP, PHT, VPA, prop, mid, THP, PB, TPM, LTG, LZP, LEV, VGB, PE, pyridoxine
General anesthesia (days)	1	13	28	0	100	191
Duration SE (days)	6	19	28	27	100	191
Outcome	Refr multifoc part E/ 10 CPS (+/- sec gen)/month, able to work, moderate response to VNS	Refr multifoc part E : daily seizures, episodes of psychosis, cogn impairment	Refr multifoc part E : 30 seizures/month, drowned during seizure	Refr multifoc part E : daily CPS (+/- sec gen), VNS, SUDEP	Refr multifoc part E, severe physical and cogn impairment	Death during SE

## Abbreviations :

M : male ; F : female ; CSF : cerebrospinal fluid ; WBC : white blood cells ; Ly : lymphocytes ; Neu : neutrophils ; gluc : glucose (mg/dl) ; prot : protein (mg/l), HSV : Herpes Simplex virus ; MRI : Magnetic Resonance Imaging ; Hc : hippocampal ; HS : hippocampal sclerosis ; NA : not available ; nl : normal ; bilat : bilateral ; PB : phenobarbital, PHT : phenytoin ; THP : thiopental ; LZP : lorazepam ; DZP : diazepam ; VPA : valproic acid ; LTG : lamotrigin ; CZP : clonazepam ; GBP : gabapentin ; TGB : topiramate ; VGB : vigabatrin ; TGB : tiagabine ; LEV : levetiracetam ; CLB : clobazam ; pred : methylprednisolone ; PE : plasma-exchange ; refr : refractory ; multifoc : multifocal ; part : partial ; E : epilepsy ; CPS : complex partial seizure ; VNS : vagal nerve stimulator ; sec gen : secondary generalization ; cogn : cognitive ; SUDEP : sudden unexpected death in epilepsy ; EEG : electroencephalogram ; SPECT : single photon emission computerized tomography ; FDG-PET : <sup>18</sup>Fluorodeoxyglucose-positron emission tomography ; CMV : cytomegalic virus ; VZV : varicella zoster virus ; LCM : lymphocytic choriomeningitis virus ; EBV : Epstein-Barr virus ; HIV : human immunodeficiency virus ; RSV : respiratory syncytial virus.

Table 2  
Evidence of multifocal seizure onset during SE or subsequent epilepsy

	Patient 1	Patient 2	Patient 3	Patient 4	Patient 5	Patient 6
EEG during SE	Rhythmic bitemporal delta activity and burst suppression	Diffuse rhythmic delta activity, left hemispheric spikes with secondary bilateral synchrony, <b>left frontal seizure onset</b> , burst suppression	NA	Diffuse rhythmic delta activity and left hemispheric sharp waves	<b>Multifocal recruiting theta and delta rhythms, burst suppression</b>	Burst suppression
EEG after SE	*Inter-ictal : excess slow activity with left temporal spikes  *Ictal : <b>independent bilateral seizure onset</b>	*Inter-ictal : <b>independent bitemporal spikes</b>  *Ictal : <b>right fronto-temporal seizure onset</b>	*Inter-ictal : excess delta activity and right epileptic activity  *Ictal : <b>multifocal seizure onset</b>	*Interictal : excess delta-activity (left > right) and centro-temporal sharp waves  *Ictal : left temporal lobe seizure onset	NA	NA
SISCOM	* <b>Right temporo-parietal hyperperfusion</b>  * <b>Left frontal lobe hyperperfusion</b>	NA	Ictal hyperperfusion of right temporal and bilateral superior parietal cortex	NA	Ictal left orbitofrontal hyperperfusion	NA
FDG-PET	Right parieto-frontal hypometabolism (inter-ictal)	NA	Normal (inter-ictal)	NA	<b>Multifocal hypermetabolism</b> (ictal)	<b>Multifocal hypermetabolism</b> (ictal)
Clinical epileptic features during SE suggesting multifocality	* <b>Right head deviation and aphasia</b>  * <b>Left eye and head deviation</b>	* <b>Right facial twitching</b>  * <b>Left eye deviation, blinking and hypersalivation</b>	NA	NA	NA	<b>Independent right/left facial twitching</b>
Clinical epileptic features following SE (video-EEG and/or history)	<b>Different SP and CPS</b> (right hypo-accusis or writing automatism) and frequent secondary GTCS (video-EEG)	<b>Right temporal lobe seizures</b> and frequent secondary GTCS (video-EEG)	<b>Different SP and CPS types</b> (hypo-accusis or micropsy) and frequent secondary GTCS (video-EG)	<b>Different SP and CPS</b> and frequent secondary GTCS (history)	Frequent secondary GTCS (history)	NA

Abbreviations :

NA : not available ; SE : status epilepticus ; EEG : electroencephalogram ; SPECT : single photon emission computerized tomography ; FDG-PET : flurodeoxyglucose-positron emission tomography ; GTCS : generalized tonic-clonic seizure ; SPS : simple partial seizure ; CPS : complex partial seizure.  
(evidence for multifocality printed in bold).

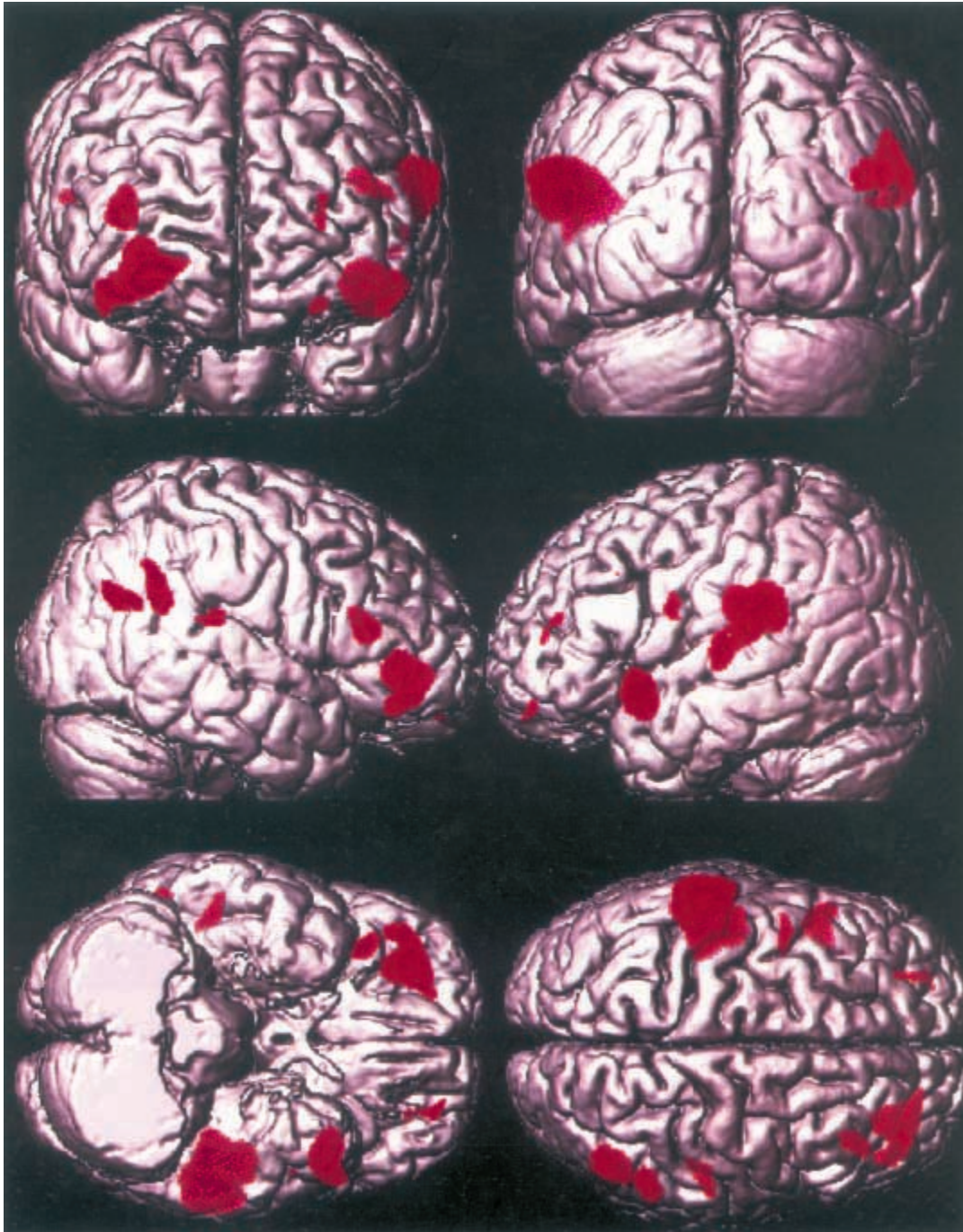


FIG. 1. — Ictal FDG-PET of the brain during a failed attempt to discontinue anesthesia as treatment of SE.

The PET study in patient 5 (Figure 1) was performed on day 29 of the SE. During the PET study, the patient was comatose and ventilated. Clinically, only a few facial twitches were observed. An eight-channel EEG was recorded during FDG uptake and revealed three partial seizures (left frontal, left posterior temporal and right temporal). FDG-PET hypermetabolic areas were projected on a surface-rendering of a 3-D MRI of the brain. The hypermetabolic areas are cortical regions of increased glucose metabolism probably representing foci of ictal activity. The ictal activity involved all cerebral lobes.

two patients (patient 2 and 3), and progressive bilateral hippocampal sclerosis in another (patient 4) (8).

In two of our patients an autopsy was obtained (patient 4 and 6). Pathologic examination in patient 4 showed bilateral hippocampal sclerosis (8), as well as cortical, deep grey nuclei and cerebellar gliosis consistent with a history of seizures and

SE. There was no evidence to support scarring as would be expected with prior encephalitic illness (9), nor were there any focal lesions or malformations. The other autopsy (patient 6) revealed evidence of neuronal loss in both hippocampi, as well as an important depletion of Purkinje cells in the cerebellum. Both changes were considered secondary to the sustained epileptic activity.

## Discussion

We describe six patients with a similar picture characterized by : 1. refractory SE as the first manifestation of epilepsy, 2. preceding febrile illness, 3. normal initial MRI of the brain, 4. normal brain pathology (biopsy) or brain pathology showing only changes secondary to prolonged seizure activity (autopsy), 5. multifocal onset in SE and/or ensuing epilepsy, 6. poor prognosis.

SE as the first manifestation of epilepsy is not unusual. In a prospective, population-based epidemiologic study of SE, DeLorenzo and colleagues reported that 58% of patients with SE did not have a previous history of epilepsy (10).

All patients presented with SE associated with fever. The preceding febrile episode in our adult patients without history of febrile convulsions or epilepsy suggested an underlying infectious etiology, i.e. acute symptomatic seizures. However, no evidence for systemic or CNS infection was found. Mild CSF lymphocytic pleocytosis, as in our patients, is a common finding after SE in the absence of meningo-encephalitis (11). Systemic infection with fever not involving the central nervous system is the most frequent etiology of SE in children, accounting for 52% of cases, but is much less common in adults, accounting for around 5% of cases (10).

Cortical dysplasia not apparent on high-resolution MRI of the brain, has been shown to be the cause of refractory, life-threatening SE (12, 13). Brain biopsies in two patients and a brain autopsy in two other patients, however, did not reveal any evidence of cortical dysplasia or other structural abnormality that could cause SE. Initial MRI did not reveal any abnormality except for meningeal enhancement in two patients, which may reflect an alteration in the blood-brain barrier, possibly related to vasogenic edema. Reversibility of these changes was demonstrated on follow-up MRI in our patients, confirming previous reports (14, 15).

Lousa and colleagues (16) reported a patient with refractory SE who responded well to plasma-exchange, and postulated an immune mechanism. Treatment with plasma-exchange and high-dose corticosteroids was, therefore, attempted in our patients 5 and 6, but failed to improve their condition.

Toxic substances, e.g. domoic acid, can cause SE (17). We had no evidence of intoxication in any of our patients.

Corey and colleagues reported that genetic factors contribute to the risk for SE (18). It is possible that genetic factors predisposed our patients to refractory SE.

Multifocal seizure onset during SE was evident in two patients and can be suspected clinically from retrospective chart review in two more (patients 1 and 2). Multifocal seizure onset in patient 5 was not

suspected on clinical grounds. For the same reasons, multifocal seizure onset during SE may have gone unnoticed in the two other patients. This is a plausible hypothesis in view of the multifocality of the subsequent epilepsy in these patients.

The outcome of SE is dependent mainly on its etiology (5, 19, 20), which remained unknown in our patients. Failure to reveal the underlying cause of SE is, however, not uncommon and in several series of SE, the etiology was classified as unknown/idiopathic in 33% (21).

Our study is a retrospective one, and probably biased towards the more severe cases. It might, therefore, well be that milder cases exist, yet have failed to come to our attention. The study of these six patients demonstrates, however, that de novo cryptogenic febrile SE progressing to refractory SE has a poor prognosis.

Based on the similarities pointed out in these patients the possibility of a distinct SE syndrome might be suggested. Further prospective studies will be required to support this hypothesis and more importantly to elucidate its etiology and optimize future treatment.

## Acknowledgement

Part of this work was funded by grant Research Fund Katholieke Universiteit Leuven Interdisciplinair Onderzoeksprogramma (IDO) /99/5. We wish to thank Prof. Dr. J.S. Duncan who attended one of the patients and kindly provided us with detailed clinical information.

## REFERENCES

1. COEYTAUX A., JALLON P., GALO BARDES B., MORABIA A. Incidence of status epilepticus in French-speaking Switzerland : (EPISTAR). *Neurology*, 2000, **55** : 693-697.
2. HESDORFFER D. C., LOGROSCINO G., CASCINO G., ANNEGERS J. F., HAUSER W. A. Incidence of status epilepticus in Rochester, Minnesota, 1965-1984. *Neurology*, 1998, **50** : 735-741.
3. Proposal for revised clinical and electroencephalographic classification of epileptic seizures. From the Commission on Classification and Terminology of the International League Against Epilepsy. *Epilepsia*, 1981, **22** : 489-501.
4. LOWENSTEIN D. H., BLECK T., MACDONALD R. L. It's time to revise the definition of status epilepticus. *Epilepsia*, 1999, **40** : 120-122.
5. FOUNTAIN N. B. Status epilepticus : risk factors and complications. *Epilepsia*, 2000, **41** (Suppl 2) : S23-30.
6. LOTHMAN E. W., BERTRAM E. H. Epileptogenic effects of status epilepticus. *Epilepsia*, 1993, **34** (Suppl 1) : S59-70.
7. SHORVON S. D. Emergency treatment of epilepsy : Acute Seizures, Serial Seizures, Seizure Clusters and Status Epilepticus. In : *Handbook of Epilepsy Treatment*. SHORVON S. D. (eds.). Blackwell Science Ltd, 2000, 173-194.

8. VAN PAESSCHEN W., DUNCAN J. S., STEVENS J. M., CONNELLY A. Longitudinal quantitative hippocampal magnetic resonance imaging study of adults with newly diagnosed partial seizures : one-year follow-up results. *Epilepsia*, 1998, **39** : 633-639.
9. TRINKA E., DUBEAU F., ANDERMANN F., HUI A., BASTOS A., LI L. M. *et al.* Successful epilepsy surgery in catastrophic postencephalitic epilepsy. *Neurology*, 2000, **54** : 2170-2173.
10. DELORENZO R. J., HAUSER W. A., TOWNE A. R., BOGGS J. G., PELLOCK J. M., PENBERTHY L. *et al.* A prospective, population-based epidemiologic study of status epilepticus in Richmond, Virginia. *Neurology*, 1996, **46** : 1029-1035.
11. BARRY E., HAUSER W. A. Pleocytosis after status epilepticus. *Arch. Neurol.*, 1994, **51** : 190-193.
12. DESBIENS R., BERKOVIC S. F., DUBEAU F., ANDERMANN F., LAXER K. D., HARVEY S. *et al.* Life-threatening focal status epilepticus due to occult cortical dysplasia. *Arch. Neurol.*, 1993, **50** : 695-700.
13. MOLYNEUX P. D., BARKER R. A., THOM M., VAN PAESSCHEN W., HARKNESS W. F., DUNCAN J. S. Successful treatment of intractable epilepsy partialis continua with multiple subpial transections. *J. Neurol. Neurosurg. Psychiatry*, 1998, **65** : 137-138.
14. LANSBERG M. G., O'BRIEN M. W., NORBASH A. M., MOSELEY M. E., MORRELL M., ALBERS G. W. MRI abnormalities associated with partial status epilepticus. *Neurology*, 1999, **52** : 1021-1027.
15. FAZEKAS F., KAPPELLER P., SCHMIDT R., STOLLBERGER R., VAROSANEC S., OFFENBACHER H. *et al.* Magnetic resonance imaging and spectroscopy findings after focal status epilepticus. *Epilepsia*, 1995, **36** : 946-949.
16. LOUSA M., SANCHEZ-ALONSO S., RODRIGUEZ-DIAZ R., DALMAU J. Status epilepticus with neuron-reactive serum antibodies : response to plasma exchange. *Neurology*, 2000, **54** : 2163-2165.
17. TEITELBAUM J. S., ZATORRE R. J., CARPENTER S., GENDRON D., EVANS A. C., GJEDDE A. *et al.* Neurologic sequelae of domoic acid intoxication due to the ingestion of contaminated mussels. *N. Engl. J. Med.*, 1990, **322** : 1781-1787.
18. COREY L. A., PELLOCK J. M., BOGGS J. G., MILLER L. L., DELORENZO R. J. Evidence for a genetic predisposition for status epilepticus. *Neurology*, 1998, **50** (2) : 558-560.
19. TOWNE A. R., PELLOCK J. M., KO D., DELORENZO R. J. Determinants of mortality in status epilepticus. *Epilepsia*, 1994, **35** : 27-34.
20. LOGROSCINO G., HESDORFFER D. C., CASCINO G., ANNEGERS J. F., HAUSER W. A. Short-term mortality after a first episode of status epilepticus. *Epilepsia*, 1997, **38** : 1344-1349.
21. TREIMAN D. M. Generalized convulsive status epilepticus in the adult. *Epilepsia*, 1993, **34** (Suppl 1) : S2-11.