

An old dissecting aneurysm of the internal carotid artery presenting as acute stroke

Andre PEETERS, Pierre GOFFETTE, Stéphanie DORBAN, Christian J. M. SINDIC and Guy COSNARD

From the Departments of Neurology (A.P., S.D., C.S.) and Neuroradiology (P.G., G.C.), Cliniques universitaires St Luc, Brussels, Belgium

Abstract

Background : In carotid artery dissections, local and ischemic manifestations usually occur within days or weeks. In some cases, persistent extracranial aneurysms cause thromboembolic complications even years after the initial event. The management of these aneurysms is still controversial.

Case description : We report the case of a 74 year old woman with a stroke due to a long standing giant dissecting aneurysm of the internal carotid artery. Medical management was insufficient to stop ongoing embolization. She was finally successfully treated with stenting.

Conclusion : Carotid artery aneurysms can become symptomatic even after many years of silence. Once medical therapy fails, endovascular treatment can avoid recurrent embolization.

Key words : Dissection ; aneurysm ; stroke ; stents.

Introduction

In carotid artery dissections, local and ischemic manifestations usually occur within days or weeks (Biousse, 1995 ; Schievink, 1994). Three angiographic patterns of dissection have been described : stenotic, occlusive and aneurysmal forms (Hart, 1983). In some cases, persistent extracranial aneurysms cause thromboembolic complications even years after the initial event (Mokri, 1990). The management of these aneurysms is still controversial.

Clinical History

A 74 year old woman presented with global aphasia and right hemiparesis at wake-up. During the subsequent hours, she recovered, and on admission, she was alert and able to execute simple commands. Severe word finding difficulties and perseverations, characteristic of Broca's aphasia, were still present. The right hemiparesis was graded 4/5. Blood pressure was 170/80 mm Hg, pulse rate 70/min, regular. Her medical history was characterized by rheumatic polyarthritis since 48 years,

treated by prednisolon 2.5 mg a day. Secondary complications of this longstanding corticotherapy were collapse of several vertebral bodies and tendon ruptures. There was no history of migraine. On physical examination there was no clinically apparent connective-tissue disorder. Blood chemistry was normal, except for a thrombocytopenia of 69.000 /mm³. A brain and neck CT disclosed a left parapharyngeal kystic mass, extending to, and eroding the base of, the skull (Fig. 1). MRI of the neck clearly identified this kystic mass as a giant internal carotid artery dissecting (ICAD) aneurysm (Fig. 2A). Diffusion-weighted MRI demonstrated multiple ischemic lesions in the left internal carotid distribution and one in the right carotid artery territory (Fig. 2B). Magnetic resonance angiography (MRA) showed the neck and the part of the aneurysm where blood is still flowing (Fig. 3A). Digital subtraction angiography (DSA) was performed in order to evaluate the feasibility of an endovascular treatment and showed a segmental dilatation, an extraluminal pouch and ICA stenosis evaluated at 75-80% (Fig. 3B). DSA of the right ICA was normal. There were no angiographic changes suggesting fibromuscular dysplasia. Cardiac monitoring during 48 hours showed normal sinus rhythm, transthoracic echocardiography showed some dilatation of the left atrium, but was otherwise normal. The patient refused transoesophageal echocardiography. Surgery was precluded due to the location of the ICAD aneurysm at the base of the skull, and also stenting was considered as difficult because of the redundancy of the left common carotid artery. It was decided to postpone endovascular treatment a few days to let the patient recover further. In the meanwhile, she was treated with antiplatelet agents. Unfortunately, on day 3, she became completely aphasic again and developed a complete right sided paralysis of the lower face and of the arm. A brain CT showed no hemorrhagic transformation or extensive infarct signs. Emergent anticoagulation with nadroparine was started at a dose of 15.000 U Axa IC, 2 times per day. The following day, the patient recovered

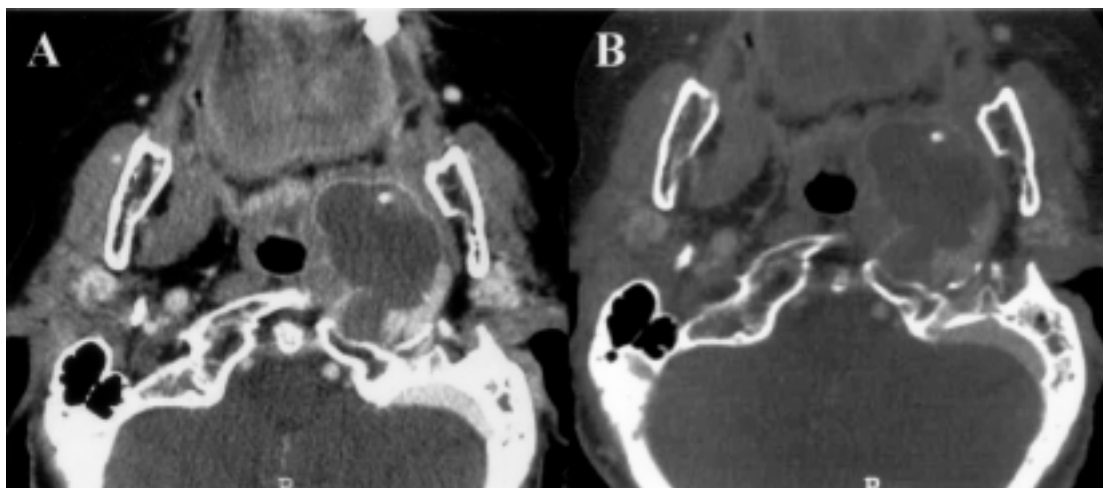


FIG. 1. — CT scan revealing a left parapharyngeal kystic mass (A). Bone window (B) demonstrates erosion of the skull base

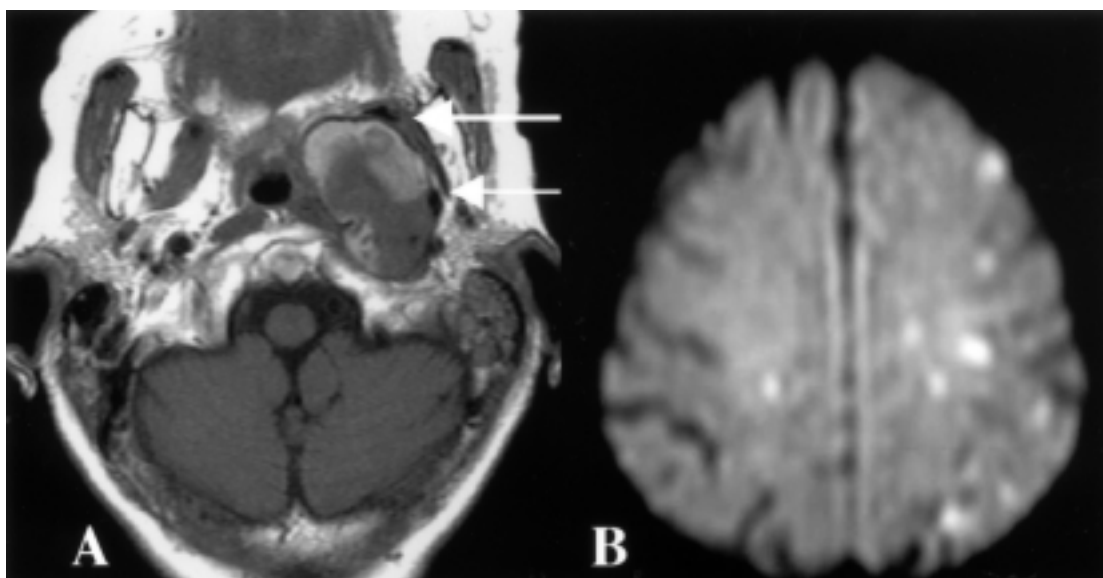


FIG. 2. — MRI shows the location of the internal carotid artery (arrows) and the kystic mass, identifying it as a dissecting aneurysm (A). Diffusion-weighted MRI shows multiple high intensity areas in the left internal carotid territory and one in the right internal carotid territory (B).

partially and it was decided to proceed to stent the ICAD aneurysm to stop definitively embolization from the aneurysmal pouch and to dilate the stenosis. Using the femoral way, the catheter failed to pass through the tortuous common carotid artery to reach the ICAD aneurysm. Thus, a direct puncture of the ICA was done and a stent (Jomed, length 38 mm) could be deployed without complication. Ticlopidin was started after the procedure. During the following week, the patient made an excellent recovery. At control follow-up 3 months later, ticlopidin was stopped and replaced by aspirin 160 mg once a day. At control follow-up at 6 months and one year later, she still did very well. On several occasions, we discussed the symptoms and signs of an ICA dissection with the patient, but neither she, nor her family recalled her having had anything similar. A skin biopsy was not performed.

Discussion

In carotid artery dissections (CAD), cerebral ischemic events usually occur within the first days or weeks, rarely later (Biousse *et al.*, 1995). Therefore, most clinicians administer anticoagulants in the acute stage and shift to antiplatelet agents after a few weeks. The long-term outcome (Leys *et al.*, 1995) and the recurrence rate (Schievink *et al.*, 1994) of CAD has been clarified, but the optimal treatment for the subgroup of patients presenting with a dissecting aneurysm remained unclear for a long time. Initially it was believed this aneurysmal forms generate a high risk of cerebral ischemia, local compression or even rupture, but this has not been confirmed in prospective series (Guillon *et al.*, 1999 ; Touzé *et al.*, 2001). The authors of these studies concluded as a

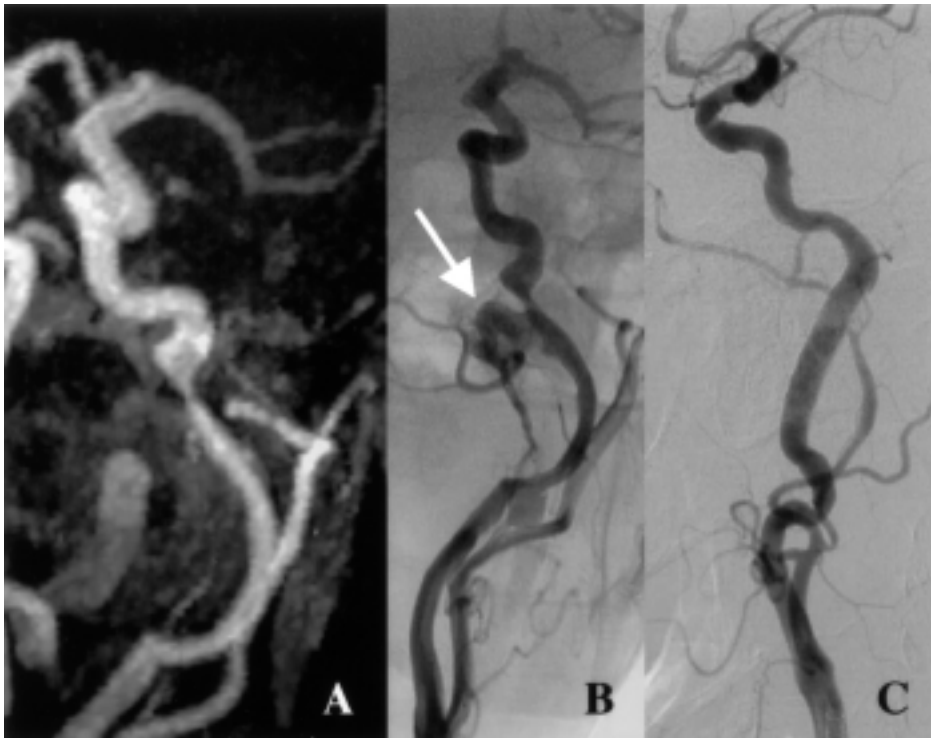


FIG. 3. — Compared to MRA (A), digital subtraction angiography (DSA) shows much better the filling of the extraluminal pouch (arrow) (B). Both examinations showed as well the 75-80% internal carotid stenosis. Stenting excluded the extraluminal pouch from circulation and restored a normal internal carotid artery diameter (C).

rule, antiplatelet therapy is sufficient and surgical or endovascular measures should be restricted to the exceptional patient who presents with ischemic complications related to this aneurysm, despite correct antithrombotic treatment. Our patient was unaware of her pathology. She could remember no symptoms, such as unilateral head or neck pain, or oculosympathetic palsy, suggestive of the acute stage of CAD. As dissecting aneurysms are reported to occur more frequently after traumatic dissections (Mokri *et al.*, 1990), we asked the patient on several occasions whether she had a history of a trauma, but the patient denied any such event. Therefore, we were unable to determine precisely the onset of the carotid artery dissection. In the series of Mokri (Mokri *et al.*, 1990), focal cerebral ischemic symptoms occurred in 5 patients with traumatic dissections up to 6-10 years after the initial trauma. The presence of bone erosion in our patient is a clear argument for a pathology present for many years. She had never had ischemic manifestations before and was, therefore, not on antiplatelet therapy when she arrived at the emergency room. Initially, we started antiplatelet therapy, but when on day 3, she worsened her stroke after the partial recovery, we started anticoagulants. This indication may be matter of discussion. As a general rule, urgent anticoagulation with the goal of preventing early recurrent stroke is not recommended (Adams *et al.*, 2003). However, certain subgroups perceived to be at high risk of recurrent embolism

may benefit from urgent anticoagulation. This was clearly the case in our patient that presented a dramatic worsening of her stroke on day 3, which we attributed to recurrent embolism from the left ICAD aneurysm. In fact, there was a marked discrepancy between the size of the cervical mass noted on the CT scan and that observed on MRA and DSA, which most likely represents the thrombus in the aneurysmal sac. As our patient already had thrombocytopenia, we were particularly afraid of hemorrhagic complications. For that reason, we preferred low-molecular-weight heparin over unfractionated heparin because of the lower risk of thrombocytopenia (Warkentin *et al.*, 1995). Cardiac investigations didn't show a potential source of emboli. Therefore, the only way to explain the lesion in the right carotid territory was at our opinion a passage of a microembolus through the anterior communicating artery. The most appropriate way to avoid definitely recurrent embolism seemed to us stenting of the ICAD aneurysm, as soon as possible. Stenting was difficult due to arterial redundancy, a common finding in patients with dissecting aneurysms (Touzé *et al.*, 2001), but after this procedure, the patient made an excellent recovery. The cause of the ICAD remained elusive in this case.

In summary, our patient illustrates that dissecting aneurysms can give rise to complications many years after the initial event. Stenting seemed in this case the proper treatment, as it enabled the

prevention of further embolization and the dilation of a hemodynamically significant stenosis at the same time. Of course, a single case does not allow the conclusion that the treatment was responsible for the favourable evolution.

REFERENCES

- ADAMS H. Jr, ADAMS R., BROTT T., DEL ZOPPO G., FURLAN A. *et al.* Guidelines for the Early Management of Patients with Ischemic Stroke. A Scientific Statement From the Stroke Council of the American Stroke Association. *Stroke*, 2003, **34** : 1056-1083.
- BIOUSSE V., D'ANGLEJEAN-CHATILLON J., TOUBOUL P. J., AMARENCO P, BOUSSER M. G. Time Course of Symptoms in Extracranial Carotid Artery Dissections. A series of 80 Patients. *Stroke*, 1995, **26** : 235-239.
- GUILLON B., BRUNEREAU L., BIOUSSE V., DJOUHRI H., LEVY C., BOUSSER M.G. Long-term follow-up of aneurysms developed during extracranial internal carotid artery dissection. *Neurology*, 1999, **53** : 117-22.
- LEYS D., MOULIN T., STOJKOVIC T., BEGEY S., CHAVOT D. Follow-Up of Patients with History of Cervical Artery Dissection. *Cerebrovasc. Dis.*, 1995, **5** : 43-49.
- MOKRI B. Traumatic and spontaneous extracranial internal carotid artery dissections. *J. Neurol.*, 1990, **237** : 356-361.
- SCHIEVINK W.I., MOKRI B., O'FALLON M. Recurrent Spontaneous Cervical-Artery Dissection. *N. Engl. J. Med.*, 1994, **330** : 393-7.
- TOUZÉ E., RANDOUX B., MÉARY E., ARQUIZAN C., MEDER J.F., MAS J.L. Aneurysmal Forms of Cervical Artery Dissection. Associated Factors and Outcome. *Stroke*, 2001, **32** : 418-423.
- WARKENTIN T., LEVINE M., HIRSH J., HORSEWOOD P., ROBERTS R., TECH M. *et al.* Heparin-induced thrombocytopenia in patients treated with low-molecular-weight heparin or unfractionated heparin. *N. Engl. J. Med.*, 1995, **332** : 1330-5.

A. PEETERS, M.D.,
 Department of Neurology,
 Cliniques universitaires St Luc,
 Avenue Hippocrate 10,
 B-1200 Brussels (Belgium).
 E-mail : andre.peeters@clin.ucl.ac.be.