

## Case report

# Metastatic germ cell testicular tumor of the eye and brain : case report

Nejmi KIYMAZ<sup>1</sup>, Bayram ÇIRAK<sup>2</sup> and Nebi YILMAZ<sup>1</sup>

<sup>1</sup>Department of Neurosurgery, Yuzuncu Yil University School of Medicine, Van, Turkey ; <sup>2</sup>Department of Neurosurgery, Pamukkale University School of Medicine, Denizli, Turkey

### Abstract

*The aim of this report is to contribute to the clinical understanding of this rare combined pathology. Intraocular metastatic tumors are rarely encountered pathologies. Mostly encountered primary sites are breast, prostate, kidney, lung and skin. Testis as a primary site for orbital metastases is rather rare. Metastasis to orbit usually occurs to periorbital structures, but to vitreus is relatively rare. Here we describe a case of intraocular metastatic tumor to the vitreus originating from testicular embryonal cell carcinoma. Patient with intraocular tumor had also intracranial metastasis. He was operated on for intracranial lesion, after an uneventful postoperative period he was discharged. 2 months later when he died, postmortem examination of the intraocular lesion reported as metastatic embryonal cell carcinoma. As a conclusion testicular embryonal cell carcinoma, even though rare, must be considered to metastasize to the eye.*

**Key words :** Germ cell tumor ; metastatic brain tumor ; metastatic intraocular tumor.

Brain metastasis in patients with disseminated nonseminomatous germ cell tumor has been considered to be rare. Intraocular metastasis of this tumour type has never been reported before. But with the improvement in handling and prolonged survival of the disseminated germ cell tumor patients its incidence has increased. For disseminated germ cell tumors chemotherapy with cisplatin, vinblastin, and bleomycine followed by surgical removal of residual tumor has given excellent results (Athanasios *et al.*, 1983). Some authors reported central nervous system metastasis to be resistant to drugs in standard therapy (Logothetis *et al.*, 1982). In this article, we report a case of testicular embryonal cell carcinoma metastasis to the brain and intraocular region at the same time.

### Case report

A 25 years old male gradually developed headache, vomiting, decreased visual acuity of

right eye, and disturbance in consciousness which first appeared 5 days before. His past history revealed an operation for a lesion located in left testicle 6 months ago. Histopathologic examination of the lesion had been reported as embryonal carcinoma. Later in postoperative period he had been given a regimen of chemotherapy consisting of bleomycine, cisplatin and etoposide for four courses. The last course of chemotherapy was just a week before the cranial symptoms started. On examination, alopecia, decreased right eye visual acuity, exophthalmos of the right eye and decreased level of consciousness were present. Magnetic resonance imaging (MR) of the brain revealed a large solid tumor in left occipital pole and peritumoral edema, there was also another lesion in the right bulbus oculi of the patient (Fig. 1, 2). Since his vision was not completely lost, surgical intervention was performed only to the intracranial lesion. The tumor was totally resected, histopathologic sections of the lesion showed an embryonal cell carcinoma metastasis. Postoperative period was uneventful. He was discharged 10 day postoperatively. 2 months after discharge he died with the diagnosis of metabolic insufficiencies secondary to disseminated malignancy in the oncology unit. Postmortem examination of the orbital lesion was reported as embryonal cell carcinoma metastasis.

### Discussion

Brain metastasis from germ cell tumour has been reported to be rare, occurring in about 4% of progressive testicular germ cell tumours (Bhala *et al.*, 2004). Even though the development of modern diagnostic techniques and prolonged survival times, central nervous system metastasis from a testicular germ cell tumour is a complication with high rates of morbidity and mortality. Spontaneous haemorrhage is known to occur frequently in germ cell tumours. Surgical removal of a large brain metastasis can improve the neurological symptoms of a patient and can eliminate the complication of haemorrhage. Good results following surgical

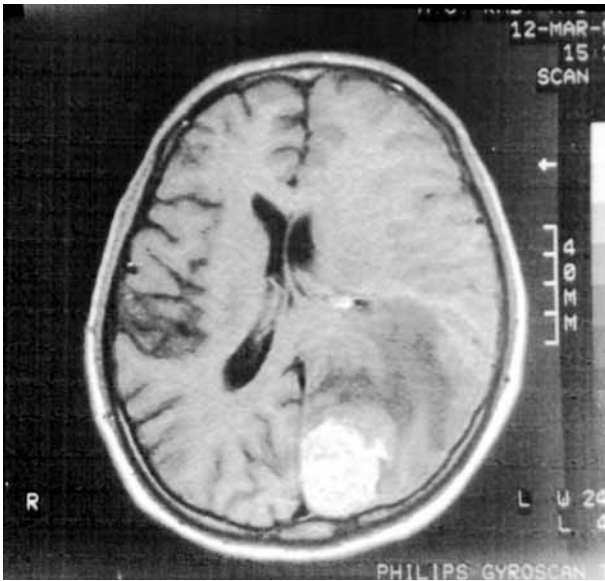


FIG. 1. — T1W axial MR section of the brain demonstrating the right occipital tumor.

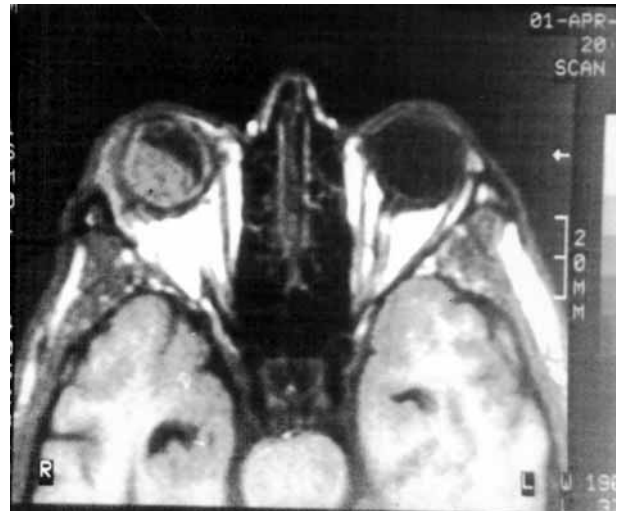

FIG. 2. — T2W axial MR section of the left eye demonstrating the metastatic intraocular tumor.

removal of metastatic brain lesion and adjuvant chemotherapy has been reported in case reports (Logothesis *et al.*, 1982).

Orbital metastasis are generally from bladder, thyroid, prostate, and breast. Lesions usually involve retroorbital or periorbital regions, intraocular metastasis is quite rare. Generally patients complain of pain on the globe, decreased visual acuity, exophthalmos, and scotomas. Lesions usually appear after the diagnosis of the primary site, but sometimes metastatic lesions may appear before the diagnosis of the primary lesion. Prognosis is not as good as only brain metastasis. After the diagnosis of an orbital metastatic lesion survival is about 25 months (Tijl *et al.*, 1992). Intraocular metastasis from a testicular germ cell tumour has never been reported before. Dual metastasis to brain and orbit at the same time has been reported only in one case in the literature from a hepatocellular carcinoma (Loo *et al.*, 1994). Our case is unique in that patient experienced both intraocular and brain metastasis at the same time in case of a germ cell tumour.

We reported this case to demonstrate the difficulty in the treatment of metastatic intraocular and brain lesions originating from a testicular germ cell tumor. Intensive chemotherapy and radiotherapy which follow surgical resection at the present time has no benefit to the survival of the patient. Surgery and adjuvant therapies are considered not to prolong the survival but to increase the life quality of the patient.

#### REFERENCES

- ATHANASSIOU A., BEGENT R. H. J., NEWLANDS E. S., PARKER D., RUSTIN G. J., BAGSHAW K. D. Central nervous system metastases of choriocarcinoma. 23 years' experience at Charing Cross Hospital. *Cancer*, 1983, **52** : 1728-1735.
- BHALA N., COLEMAN J. M., RADSTONE C. R., HORSMAN J. M., GEORGE J., HANCOCK B. W., HATTON M. Q., COLEMAN R. E. The management and survival of patients with advanced germ-cell tumours : improving outcome in intermediate and poor prognosis patients. *Clin Oncol.*, 2004, **16** : 40-47.
- LOGOTHESIS C. J., SAMUELS M. L., TRINDADE A. The management of brain metastases in germ cell tumors. *Cancer*, 1982, **49** : 12-18.
- LOO K. T., TSUI W. M., CHUNG K. H., HO L. C., TANG S. K., TSE C. H. Hepatocellular carcinoma metastasizing to the brain and orbit : report of three cases. *Pathology*, 1994, **26** : 119-122.
- TIJL J., KOORNNEEF L., EIJPE A., THOMAS L., GONZALEZ D., VEENHOF C. Metastatic tumors to the orbit- management and prognosis. *Graefes Arch. Clin. Exp. Ophthalmol.*, 1992, **230** : 527-530.

Dr. N. KIYMAZ, M.D., Assistance Professor,  
Yuzuncu Yil Üniversitesi Tıp Fakültesi, Arastırma,  
Hastanesi, Beyin Cerrahisi,  
65300 Van (Turkey).  
E-mail : nejmikiymaz@yahoo.co.uk.