



Hyperexcitability of the facial nerve in tuberculous meningitis

Maria AIGUABELLA¹, Jordi GASCÓN-BAYARRI¹, Jordi MONTERO¹, Miguel SANTÍN² and Carmen PEÑA²

¹Department of Neurology, ²Department of Infectious Diseases, Bellvitge University Hospital, L'Hospitalet de Llobregat, Spain

Abstract

Introduction: Facial myokymias (FM) are continuous, involuntary, undulating movements of the facial muscles associated with spontaneous electromyographic activity, such as fasciculations and myokymic discharges. They may occur in healthy individuals, or be secondary to multiple sclerosis, posterior fossa tumors, or an inflammatory process.

Patient and results: We describe the case of a 31-year-old man who presented with headache, vomiting, low fever, and disorientation. Cerebrospinal fluid findings included low glucose and high protein content and lymphocyte pleocytosis, with positive culture for *Mycobacterium tuberculosis*. The patient was diagnosed with tuberculous meningitis. Magnetic resonance imaging showed high contrast enhancement in the basal meninges and a left frontal tuberculoma. Over the course of the disease, he experienced FM and persistent, involuntary contraction of the facial muscles. The electromyogram recorded myokymic discharges.

Discussion: Tuberculous meningitis is a rare cause of FM. The presence of myokymic discharges on electromyography verified the peripheral origin of facial nerve hyperexcitability in this case, in contrast to persistent contraction of the facial muscles, which has a central origin. The phenomena were transitory and only positive symptoms were observed, with no facial nerve injury.

Conclusion: Tuberculous meningitis is a rare cause of facial nerve hyperexcitability, which can have a peripheral, nuclear, or supranuclear origin.

Key words: Tuberculous meningitis; facial palsy; facial hyperexcitability; facial myokymia.

Introduction

Tuberculous meningitis is an uncommon form of extrapulmonary tuberculosis (5% of cases) that can cause focal signs, usually secondary to the development of hydrocephaly, vasculitis, or tuberculomas (1). Affected patients may present symptoms related to the cranial nerves (2), including hyperexcitability phenomena.

Hyperexcitability of the facial nerve can cause abnormal axonal discharges such as fasciculations, myokymic discharges, and hemifacial spasm. These events may be observed after demyelination or axonotmesis of the facial nerve (3) followed by aberrant innervation, or in involuntary states of increased motor unit activity, which occurs in brainstem lesions and some central nervous disorders (blepharospasm, dystonia, facial tics).

Facial myokymia (FM) is a clinical phenomenon manifesting as involuntary, continuous, slow, undulating movements of the facial muscles that may be associated with limited motor unit discharges (4). Myokymic discharges consist of grouped simple potentials or repeated discharges at a uniform frequency (2-60 Hz), which are followed by a short period of silence (5) and are caused by ectopic discharges in the motor axon (6).

We describe a case of tuberculous meningitis with FM and persistent, involuntary contraction of the facial muscles.

Patient and results

A 31-year-old man from Ghana experienced headache with vomiting, asthenia, anorexia, and weight loss over 7 days. His temperature was 37.7°C, blood pressure 140/50, and heart rate 61 bpm. The remainder of the general physical examination was normal. The patient was conscious, but temporally and spatially disoriented and showed signs of meningism.

The standard laboratory tests, chest X-ray, and cranial CT scan were normal. Cerebrospinal fluid examination showed 280 cells/mm³ (98% lymphocytes and 2% polymorphonuclear leukocytes), glucose 1.3 mmol/L, proteins 3.19 g/L, and positive PCR study and culture for *Mycobacterium tuberculosis*. The initial magnetic resonance imaging (MRI) study revealed high contrast enhancement in the basal

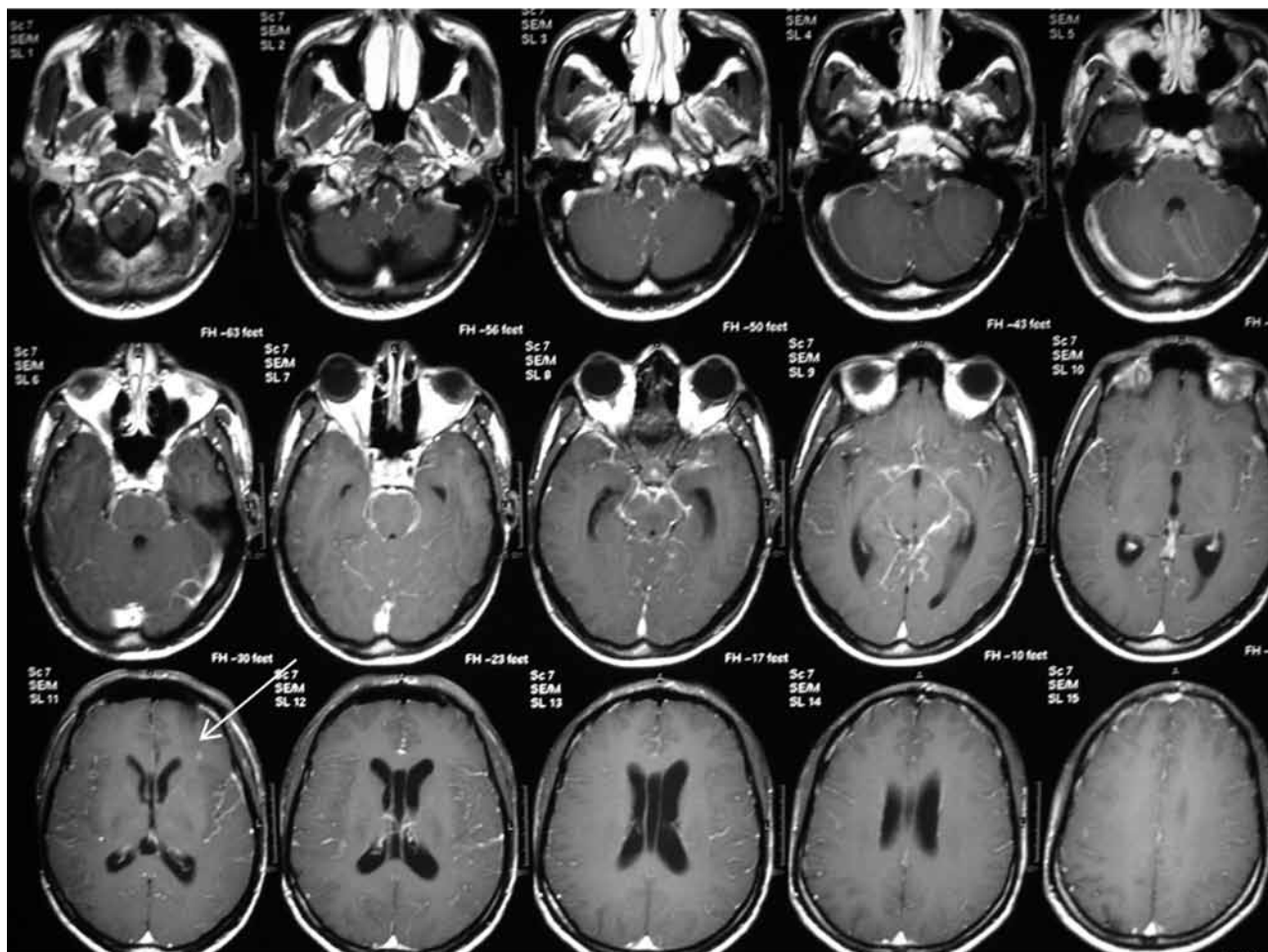


FIG. 1. — High contrast enhancement in the basal meninges. Arrow indicates the left frontal tuberculoma

meninges, and a small left frontal intraparenchymatous lesion consistent with a tuberculoma (Fig. 1).

Treatment was started with rifampicin, isoniazid, ethambutol, and glucocorticoids. Initially, the patient's condition worsened, with intense headaches and development of hydrocephaly. Nevertheless, a gradual improvement was subsequently observed. At 6 weeks after admission, and following tapering of the glucocorticoid dose, the patient presented twitching in the left-hand corner of the mouth due to tonic contraction of the homolateral facial muscles, FM in the left orbicularis oris and oculi muscles (Fig. 2), and generalized areflexia. A second MRI showed increased contrast enhancement in the basal meninges. The blink reflex revealed normal bilateral R1 latency and normal contralateral R2 latency. The homolateral R2 was difficult to assess due to persistent facial contraction, which interrupted the silent period between R1 and R2, but the R2 response seemed enhanced. During nerve stimulation, post-discharge phenomena were observed. This appeared with both

stimulations: in the proximal facial nerve and in superior branch (Møller-Janetta response) (6, 7). Needle electrodes recorded myokymic discharges only in the orbicularis oris (Fig. 3), and not in the other facial muscles (frontal, orbicularis oculi). After increasing the glucocorticoid dose and initiating vitamin B6 treatment, the patient's condition improved. The myokymia and facial muscle contractions disappeared 2 months later.

Discussion

Facial myokymia often occurs in healthy individuals as a self-limited, work- and stress-related event. The most common underlying pathologies causing this condition are multiple sclerosis, posterior fossa tumors, inflammatory diseases, and gliomas, which typically cause FM of the frontal muscles (8, 9). When FM persists, it is essential to perform an imaging study to rule out these diseases. Guillain-Barré syndrome is another common cause, although in



FIG. 2. — Persistent contraction of left facial muscles

most cases the myokymic discharges are only observed at the beginning of the disease on electromyographic analysis (10). A large number of other causes are mentioned in the literature, including tuberculous meningitis. We found only two cases of hyperexcitability of the facial nerve related to tuberculosis: tuberculoma of the pons with FM and facial weakness (11) and hemifacial spasm in tuberculous meningitis (12). It should be noted that, unlike the reported cases, in which FM was associated with facial palsy, our patient did not show this sign.

We consider that the FM observed in our patient originated at the axonal level because myokymic discharges were seen in the orbicularis oris on electromyography, and MRI did not document a parenchymal brainstem lesion. These FM are always caused by ectopic discharges in the facial nerve (4) due to focal hyperexcitability phenomena attributed to demyelination, which is probably related to inflammation of the meninges at the emergence of the facial nerve. From a theoretical viewpoint, we cannot rule out an "intra-axial" demyelinating focus in the facial nerves, as has been proposed in multiple sclerosis. However, in most reported cases, the origin of FM is suggested to be central (7) or nuclear and caused by spontaneous activity of the second motor neurons (without myokymic discharges) (6). Generalized areflexia initially attributed to the anti-tuberculous drugs was detected, but neurophysio-

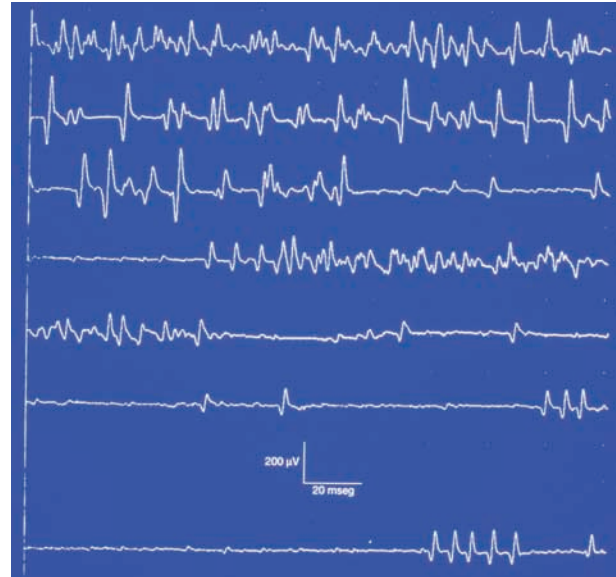


FIG. 3. — Myokymic discharges in orbicularis oris

logic study ruled out polyneuropathy. After 2 months, the areflexia resolved and was attributed to polyradiculitis caused by tuberculous meningitis.

The patient presented experienced peripheral axonal hyperexcitability of the facial nerve, the same pathophysiological mechanism observed in patients with Guillain-Barré syndrome, hemifacial spasm (7), latent tetany (13), neuromyotonia (Isaac's syndrome), and facial hyperactivity following radiotherapy (14). He also showed facial hyperactivity of central origin manifested by persistent involuntary contraction and increased cutaneous reflex response (R2 of the blink reflex), although this response was only homolateral. These phenomena were likely caused by a state of increased brainstem excitability, similar to that observed in hemifacial spasm, in which both types of hyperexcitability are usually combined. This speculative possibility is not possible to demonstrate with neurophysiological methods. In any case, the phenomenon was transitory, showed only positive symptoms, and did not cause axonal facial nerve injury or sequelae affecting the brainstem.

REFERENCES

1. Thwaites GE, Tran TH. Tuberculous meningitis: too many questions, too few answers. *Lancet Neurol.* 2005;4(3):160-70.
2. Nicolls DJ, King M, Holland D, Bala J, del Rio C. Intracranial tuberculomas developing while on therapy for pulmonary tuberculosis. *Lancet Infect Dis.* 2005;5(12):795-801.

3. Cossu G, Valls-Solé J, Valldeoriola F, Muñoz E, Benítez P, Aguilar F. Reflex excitability of facial motoneurons at onset of muscle reinnervation after facial nerve palsy. *Muscle Nerve*. 1999;22(5):614-620.
4. Gutmann L. AAEM minimonograph #37: Facial and limb myokymia. *Muscle nerve*. 1991;14:1043-9.
5. Kimura J. *Electrodiagnosis in diseases of nerve and muscle. Principles and practice* (3rd ed). Oxford University Press. New York. 2001.
6. Valls-Solé J, Montero J. Role of EMG evaluation in muscle hyperactivity syndromes. *J Neurol*. 2004; 251(3):251-260.
7. Montero J, Junyent J, Calopa M, Povedano M, Valls-Solé J. Electrophysiological study of ephaptic axono-axonal responses in hemifacial spasm. *Muscle Nerve*. 2007;35(2):184-8.
8. Radu EW, Shorpil V, Kaeser HE. Facial myokymia. *Eur Neurol*. 1975;13(6):499-512.
9. Andermann F, Cosgrove JBR, Lloyd-Smith DL, Gloor P, Mc Naughton FL. Facial myokymia in multiple sclerosis. *Brain*. 1961;84:31-44.
10. Van Zandycke M, Martin JJ, Vande Gaer L, Van den Heyning P. Facial myokymia in the Guillain-Barré syndrome: a clinicopathologic study. *Neurology*. 1982;32(7):744-8.
11. Boghen D, Filiatrault R, Descarries L. Myokymia and facial contracture in brainstem tuberculoma. *Neurology*. 1977;27(3):270-2.
12. Sandyk R. Hemifacial spasm in tuberculous meningitis. *Postgrad Med J*. 1983;59(695):570-1.
13. Bostock H, Baker M, Reid G. Changes in excitability of human motor axons underlying post-ischaemic fasciculations: evidence for two stable states. *J Physiol*. 1991;441:537-557.
14. Marti-Fàbregas J, Montero J, López-Villegas, Quer M. Post-irradiation neuromyotonia in bilateral facial and trigeminal nerve distribution. *Neurology*. 1997;48(4):1107-9.

Dr. Jordi Gascón-Bayarri,
Servei de Neurologia,
Hospital Universitari de Bellvitge,
Avda. de la Feixa Llarga s/n,
08907-L'Hospitalet de Llobregat,
Barcelona (Spain).
E-mail: 32535jgb@comb.cat;
jordigneuro@bellvitgehospital.cat