



## Phantoms in the brain: transient mass in the posterior fossa after traumatic cervical SCI and vertebral artery obstruction

F. AYUGA-LORO, M. TORRES-LLACSA, A. BROCALERO, J. FLORENSA-VILA and A. OLIVIERO  
Hospital Nacional de Paraplégicos, SESCAM, Finca “la Peraleda” s/n, 45071 Toledo, Spain

### Case summary

We describe the neuroimages of a patient who suffered from a traumatic spinal cord injury at cervical level and a longitudinal bulbospinal infarct secondary to the right vertebral artery obstruction. Twenty days later, a mass in the posterior fossa and a tetraventricular hydrocephalus were detected. This was not caused by a bleeding (SWI sequence did not show hemoglobin degradation products). The mass did not show contrast enhancement. MRI findings in the present case indicate a possible collapse of a portion of the ischemic brain tissue during the liquefactive necrosis phase of the infarction, and consequent fibrine coagulum (1, 2). The mass disappeared a few months later without any specific treatment.

### REFERENCES

1. Nakaguchi H, Miyamoto M. Obstructive hydrocephalus caused by intraventricular collapse of malacotic brain. Case report. *J Neurosurg.* 2001 Jul; 95(1):119-21.
2. Okazaki H. *Fundamentals of Neuropathology: Morphologic Basis of Neurologic Disorders*, ed 2. New York: Igaku-Shoin, 1989.

Antonio Oliviero,  
Hospital Nacional de Paraplégicos,  
SESCAM Finca “la Peraleda” s/n,  
45071 Toledo (Spain).  
E-mail: antonioo@sescam.jccm.es

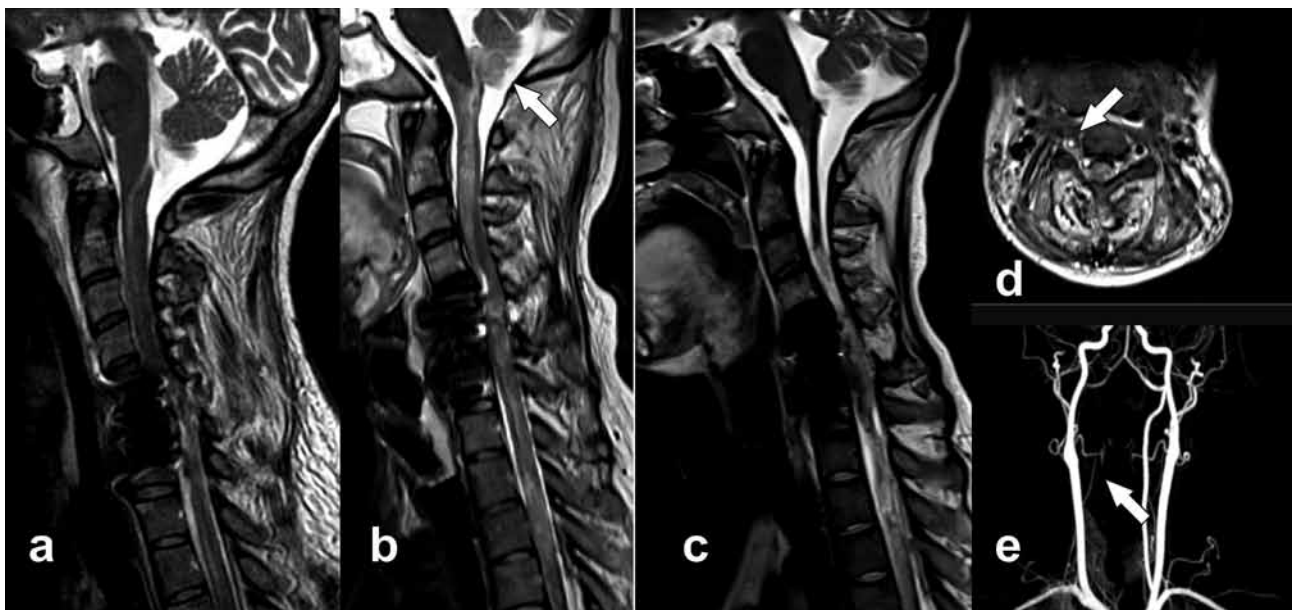


FIG. 1. — MRI shows a traumatic lesion in the cervical spine (a). Twenty days later, a mass in posterior fossa was evident (b). This mass disappeared after 6 months (c). Vertebral artery obstruction (d, e).