



## Acute shoulder-girdle neuralgic amyotrophy (Parsonage-Turner Syndrome with saphenous nerve involvement)

F. GINANNESCHI<sup>1</sup>, A. MALANDRINI<sup>2</sup>, L. MONTI<sup>3</sup> and A. ROSSI<sup>1</sup>

<sup>1</sup>Department of Neurological, <sup>2</sup>Department of Neurological, Neurosurgical and Behavioural Sciences, Neurometabolic Unit, University of Siena, Italy;

<sup>3</sup>Neuroradiology, University Hospital of Siena, Italy

### Abstract

*Parsonage-Turner syndrome (PTS) is a relatively rare cause of upper extremity weakness and pain. There is currently no effective treatment for PTS although corticosteroids are recommended. Here we report the case of a man with acute PTS and exceptional involvement of both saphenous nerves, advantageously treated with intravenous immunoglobulin.*

**Key words:** Intravenous immunoglobulin; Parsonage-Turner syndrome; Saphenous nerve.

### Introduction

Parsonage-Turner syndrome (PTS) is a relatively rare cause of upper extremity weakness and dysfunction. It involves neuritis mainly affecting the brachial plexus. There is currently no effective treatment for PTS; although corticosteroids are recommended, no definite improvement has been documented. Here we report an atypical case of PTS, with documented involvement of both saphenous nerves and advantageously treated with intravenous immunoglobulin (IV Ig).

### Case report

A 37-year-old man developed sudden severe pain in the neck and right arm, followed by weakness, hypoesthesia and hypotrophy of the right shoulder girdle and proximal right arm. Five weeks later the patient developed marked weakness of the left wrist extensor muscles, cramps and hypoesthesia of the medial right leg. There was a history of heavy exercise preceding the acute pain. Electromyography (EMG) carried out 6 weeks after onset of symptoms revealed acute denervation in the form of fibrillations and positive sharp waves and a reduced recruitment pattern in the right infraspinatus, supraspinatus,

deltoid, biceps brachii, left brachioradialis and wrist extensor muscles. EMG of the leg muscles and nervous conduction parameters of deep and superficial peroneal, tibial and sural nerves were normal. The sensory nerve action potential (SNAP) of the right saphenous nerve was absent, and that of the left one was severely reduced (see Table 1). Cerebrospinal fluid examination, standard neuroimmunological screening and tests for neurotropic viruses were all negative. Nuclear magnetic resonance (NMR) of the brachial plexus showed bilaterally thickened and hyperintense brachial plexus trunks (Fig. 1), and diffuse high signal intensity throughout the right supraspinatus and infraspinatus muscles (Fig. 2). The patient was treated with IV methylprednisolone (1 g/day for 5 days) followed by oral prednisone (25 mg/day). Since clinical status and electrophysiological data were unchanged after corticosteroid treatment, we started treatment with IV Ig (0.4 g/kg/day for 5 days). After five days of IV Ig infusion the patient reported improvement in muscle strength of the right arm with disappearance of hypoesthesia in the lower limb and cramps. EMG studies at this time showed evidence of reinnervation potentials in affected muscles, indicating ongoing recovery, and SNAP of the right saphenous nerve could be elicited. Table 1 shows electrophysiological values before and after the treatment with IV Ig. There were no evident conduction blocks.

### Discussion

The characteristic pattern of pain followed by profound weakness are generally the clues used to diagnose PTS. EMG and NMR are often crucial in confirming a diagnosis of PTS, as there is no specific diagnostic test. Pain is often described as a severe ache or throbbing radiating from the shoulder distally down the arm or proximally into the neck.

Table 1  
Nerve conduction parameters, before and after IV Ig treatment

	R Saphenous (medial leg-malleolus)	L Saphenous (medial leg-malleolus)	R Musculocutaneus (Erb-Biceps brachii)	L Musculocutaneus (Erb-Biceps brachii)	R Suprascapular (Erb-Suprascapular)	R Suprascapular (Erb-Infraspinatus)	R Axillary (Erb-Deltoid)	R Ulnar CMAP (from the ADM muscle)	R Ulnar SAP (fifth finger-wrist)	R Median (wrist-APB)
Basal	SCV: 32 m/s. Amp: 2.1 $\mu$ V.	ML: 7.65 ms. Amp: 0.87 mV.	ML: 6 ms. Amp: 3.8 mV.	ML: 3.65 ms. Amp: 3.7 mV.	ML: 4.2 ms. Amp: 1 mV.	ML: 7.4 ms. Amp: 1.4 mV.	DML: 3 ms. MCV: wr-el 55; el-ax 62 mV. Amp: 12 mV. "F" wave: 28.7 ms.	SCV: 55 m/s. Amp: 7 $\mu$ V.	"F" wave: 29.7 ms.	
Post IV Ig	SCV: 32 m/s Amp: 1.3 $\mu$ V	ML: 6.15 ms. Amp: 1.3 mV.	ML: 4.5 ms. Amp: 4.9 mV.	ML: 3.25 ms. Amp: 5.4 mV.	ML: 4 ms. Amp: 1.5 mV.	ML: 7.1 ms. Amp: 1.6 mV.	DML: 3 ms. MCV: w-e 57; e-a 64 mV. Amp: 12 mV. "F" wave: 28.6 ms.	SCV: 56 m/s. Amp: 7 $\mu$ V.	"F" wave: 29 ms.	

IV Ig: intravenous immunoglobulin; R: right; L: left; Amp: amplitude; DML: distal motor latency; ML: motor latency; CMAP: compound muscle action potential; MCV: motor conduction velocity; wr: wrist; el: elbow; ax: axilla; SCV: sensory conduction velocity; SAP: sensory nerve action potential; APB: abductor pollicis brevis; ADM: abductor digiti minimi. Stimulation and recording sites are described in parenthesis for every nerve.

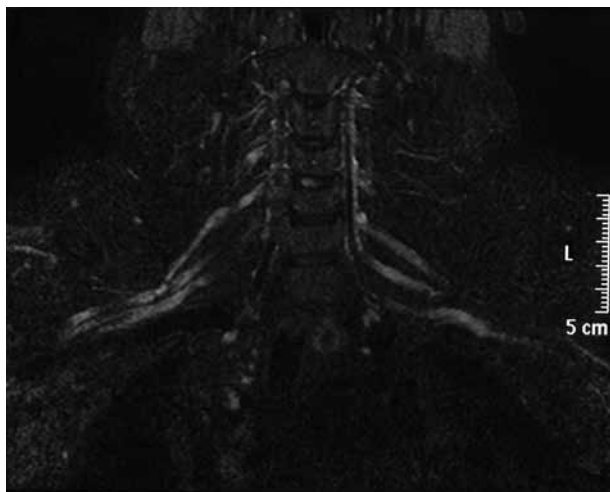


FIG. 1. — Coronal T2-weight STIR (Short inversion Time Inversion Recovery) NMR image showing thickened and hyperintense brachial plexus trunks.

These symptoms may last for a few hours or may persist for up to three or more weeks. Muscle weakness usually occurs after the pain has subsided, with an estimated 70% of sufferers experiencing weakness 2 weeks after the onset of symptoms. Many factors have been proposed as cause of the neuritis, including trauma, infection, viral disease, heavy exercise, immunization, genetic factor and autoimmune conditions.

Although the original descriptions of PTS describe a global palsy affecting muscles in the shoulder region, nerves outside the distribution of the brachial plexus may also be affected. Indeed, about 20% of attacks of idiopathic PTS occur outside the brachial plexus: phrenic, intercostals, cranial (VII, IX, X, XI and XII), recurrent laryngeal, facial and abdominal nerves can be involved in PTS. The present study shows electrophysiological and clinical involvement of lower limbs nerves in a case of PTS. Our patient exhibited typical involvement of the suprascapular nerve with denervation of supraspinatus and infraspinatus muscles. Substantial supportive evidence of atrophy and neurogenic edema in the shoulder muscles was obtained by NMR, confirming that NMR can improve the diagnostic accuracy of PTS(2). Involvement of the lumbosacral plexus or lower limb nerves seems to be exceptional in PTS. Van Alfen *et al.* (1) reported a case of possible involvement of the lumbosacral plexus during PTS attacks. However, it was only presumed on the basis of hypaesthesia and paraesthesia, without electrophysiological evidence of muscle or nerve alterations. In the present case, five weeks after pain and

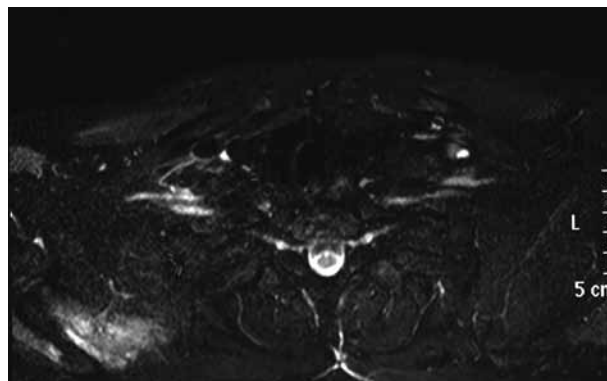


FIG. 2. — Axial T2-weight STIR (Short inversion Time Inversion Recovery) NMR image showing increased signal in right supraspinatus and infraspinatus muscles.

weakness of the right shoulder girdle and arm, the patient developed hypoesthesia of the medial right leg. Sensory fibre conduction of the right and left saphenous nerves was severely and moderately altered, respectively.

Histological studies have shown that the pathological process can cause focal damage to one or more nerve fascicles, presumably caused by an immune B- or T-cell mediated response (3). Treatment of PTS attacks with corticosteroids has therefore been considered useful, though without definite improvement; however, positive effects have also been reported in two patients with hereditary (4) and idiopathic (5) PTS after intravenous IV Ig. In our patient, corticosteroid treatment was ineffective but rapid relief of symptoms of the lower and upper limbs was obtained after i.v. infusion of Ig.

The present study confirms the notion that PTS is a potentially diffuse, immune mediated disorder of the peripheral nervous system. It also underlines the need for randomised clinical trials to establish an optimal treatment regimen for PTS and sound prognosis.

#### REFERENCES

1. van Alfen N, van Engelen BG. The clinical spectrum of neuralgic amyotrophy in 246 cases. *Brain*. 2006; 129:438-50.
2. Scalf RE, Wenger DE, Frick MA, Mandrekar JN, Adkins MC. MRI findings of 26 patients with arsonage-Turner syndrome. *AJR Am J Roentgenol*. 2007; 189:W39-44.
3. van Alfen N, Gabreels-Festen AA, Ter Laak HJ, Arts WF, Gabreels FJ, van Engelen BG. Histology of hereditary neuralgic amyotrophy. *J Neurol Neurosurg Psychiatry*. 2005;76:445-447.

4. Ardolino G, Barbieri S, Priori A. High dose intravenous immune globulin in the treatment of hereditary recurrent brachial plexus neuropathy. *J Neurol Neurosurg Psychiatry*. 2003;74:550.
5. Inoue C, Hayashi A, Yoshizawa T, Sato A, Shoji S. Effect of intravenous immunoglobulin therapy in a case of idiopathic recurrent brachial and lumbosacral plexopathy. *Rinsho Shinkeigaku*. 1999;39:661-664.

Dott. Federica Ginanneschi,  
Department of Neurological and  
Behavioural Sciences,  
Clinical Neurophysiology Unit,  
University of Siena,  
Policlinico Le Scotte,  
Viale Bracci 1,  
53100 Siena (Italy).  
E-mail: ginanneschi@unisi.it